

January 2012

Histopathology confirms White-Nose Syndrome in bats in Europe

Jiri Pikula

Hana Bandouchova

Landislov Novotny

Follow this and additional works at: https://digitalcommons.usf.edu/kip_articles

Recommended Citation

Pikula, Jiri; Bandouchova, Hana; and Novotny, Landislov, "Histopathology confirms White-Nose Syndrome in bats in Europe" (2012). *KIP Articles*. 2389.

https://digitalcommons.usf.edu/kip_articles/2389

This Article is brought to you for free and open access by the KIP Research Publications at Digital Commons @ University of South Florida. It has been accepted for inclusion in KIP Articles by an authorized administrator of Digital Commons @ University of South Florida. For more information, please contact digitalcommons@usf.edu.

Histopathology Confirms White-Nose Syndrome in Bats in Europe

Jiri Pikula,¹ Hana Bandouchova,¹ Ladislav Novotný,¹ Carol U. Meteyer,² Jan Zukal,^{3,4} Nancy R. Irwin,⁵ Jan Zima,³ and Natálie Martínková^{3,6,7} ¹ University of Veterinary and Pharmaceutical Sciences, Palackého 1/3, 612 42 Brno, Czech Republic; ² US Geological Survey, National Wildlife Health Center, 6006 Schroeder Road, Madison, Wisconsin 53711-6223, USA; ³ Institute of Vertebrate Biology, Academy of Sciences of the Czech Republic, v.v.i., Květná 8, Brno, 603 65 Czech Republic; ⁴ Department of Botany and Zoology, Masaryk University, Kotlářská 2, 611 37 Brno, Czech Republic; ⁵ Department of Biology, York University, York YO10 5DD, UK; ⁶ Institute of Biostatistics and Analyses, Masaryk University, Kamenice 3, 625 00 Brno, Czech Republic; ⁷ Corresponding author (email: martinkova@ivb.cz)

ABSTRACT: White-nose syndrome, associated with the fungal skin infection geomycosis, caused regional population collapse in bats in North America. Our results, based on histopathology, show the presence of white-nose syndrome in Europe. Dermatohistopathology on two bats (*Myotis myotis*) found dead in March 2010 with geomycosis in the Czech Republic had characteristics resembling *Geomyces destructans* infection in bats confirmed with white-nose syndrome in US hibernacula. In addition, a live *M. myotis*, biopsied for histopathology during hibernation in April 2011, had typical fungal infection with cupping erosion and invasion of muzzle skin diagnostic for white-nose syndrome and conidiospores identical to *G. destructans* that were genetically confirmed as *G. destructans*.

Key words: *Geomyces destructans*, geomycosis, histopathology, *Myotis myotis*, white-nose syndrome.

White-nose syndrome (WNS) is an emerging disease, associated with the fungus *Geomyces destructans*, that is spreading among hibernating bats in North America (Blehert et al., 2009). Dermatohistopathology confirms WNS characterized by fungal invasion of living tissue and epidermal cupping erosions (Meteyer et al., 2009). Field clinical signs of WNS in bats include a suite of descriptors including white fungal growth on hairless parts of wings, muzzle, and ears, aberrant behavior in winter, loss of fat reserves, and increased mortality at affected sites (Foley et al., 2011). Mass mortality of bats can lead to regional population collapse and extinction (Frick et al., 2010).

In Europe, *G. destructans* was first identified morphologically from culture and sequencing of *ITS* and *SSU* rRNA regions from affected bats in 2008 (Wibbelt

et al., 2010). Photographs of bats with white muzzles have been taken sporadically over several decades, but lately there has been an increase in these observations (Martínková et al., 2010). Recent genetic evidence confirms that *G. destructans* is widespread in Europe, but mass mortality has not been observed (Puechmaile et al., 2011b). There has been no histologic study of bats with geomycosis in Europe because bats may not be euthanatized without a permit, and detection of the fungus was therefore restricted to live bats without histopathologic examination. We present the histopathologic confirmation of WNS in bats from Europe.

A carcass of a greater mouse-eared bat (*Myotis myotis*) with white fungal patches on its muzzle was found in Stará Drátenická cave (Moravian Karst, Czech Republic) on 6 March 2010, during a winter survey. Conidiospores and hyphae morphologically identical to *G. destructans* were found on an adhesive tape sample taken from the bat in the cave (Fig. 1a), but cultures and PCR on this sample were negative (sample 5^t, Martínková et al., 2010). No other bats in the hibernaculum (29 bats of seven species) had signs of fungal infection.

Five greater mouse-eared adult bat carcasses were found 12 days after the survey on the floor of Byčí skála cave (Moravian Karst, Czech Republic; ~3 km from Stará Drátenická cave) approximately 40 m from the entrance. The carcasses were collected and frozen at –20 C for later examination. In 2010, 1,192 greater mouse-eared bats were counted in Byčí skála cave, hibernating alone or in clusters of around 30 individuals

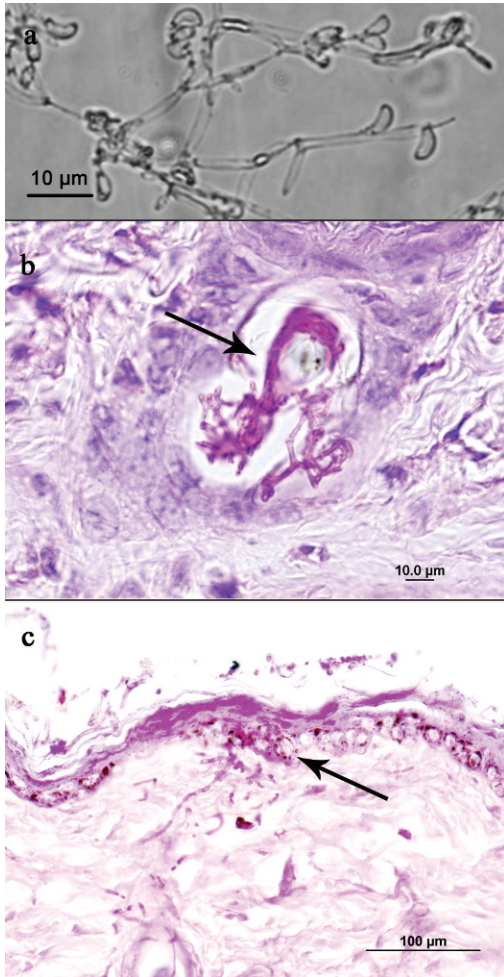


FIGURE 1. *Geomyces destructans* infection in bats (*Myotis myotis*) found dead in hibernacula in two caves in the Czech Republic. (a) Hyphae and spores morphologically identical to *G. destructans*, collected using adhesive tape from the muzzle of a bat from Stará Drátenická cave. (b) Fungal growth on the muzzle of a bat from Byčí skála cave resulting in colonization of the hair follicle (arrow). Periodic acid–Schiff (PAS) stain. (c) Fungal growth over epidermis of a bat from Byčí skála cave with hyphae obscuring the basement membrane and invading the superficial dermis (arrow). Fungal growth in the dermal tissue consisted of dichotomic branching hyphae, ~2 µm in diameter, with occasional septa. PAS stain.

in crevices in high domes. In a previous study, *G. destructans* was genetically confirmed in two live bats found deeper in the cave than the carcasses discussed in this paper (Martínková et al., 2010).

Gross visual inspection of the six dead bats (one from Stará Drátenická cave and five from Byčí skála cave) in the laboratory showed no visible fungal growth or skin lesions, although fungal growth was present while the bat from Stará Drátenická cave remained on the cave wall. The body condition was poor to moderate with low adipose tissue stores. The mean body weight of the six bat cadavers was 18 g, which contrasts with live bats during hibernation that weigh about 26 g (Krapp, 2001). The upper jaw together with the skin, wing membranes (plagiopatagium), and lungs were dissected for histopathologic examination. Formalin-fixed samples containing bones of the upper jaw were decalcified using formic acid to facilitate preparation of sections. Wing membranes were rolled for paraffin embedding. Serial tissue sections of 5 µm were prepared and stained with periodic acid–Schiff stain. Internal organs were stained with hematoxylin and eosin.

No fungal infection was seen in the microscopic sections of wing skin from four bats, but fungal colonization of the skin of two bats from Stará Drátenická and Byčí skála caves was heavy. Although autolysis was present, organized hyphae were seen in all layers of epidermis of the muzzle and deep in the hair follicles (Fig. 1b). The hyphae penetrated the basement membrane of the epidermis with focal pigmentary incontinence and invaded the superficial and deep dermis and underlying connective tissue (Fig. 1c). Fungal hyphae and detritus were seen in the nasal cavity that may have been postmortem invasion. Hyphae were also present in the nasal cartilage perichondrium and endomysium of nasal muscles. No reactive inflammatory response was observed, except for sporadic small pustules containing hyphae in the dermal tissue. Lungs were congested and alveoli filled with slightly eosinophilic liquid, probably as a result of postmortem changes.

An 24-g, adult, male greater mouse-eared bat, hibernating in Byčí skála cave

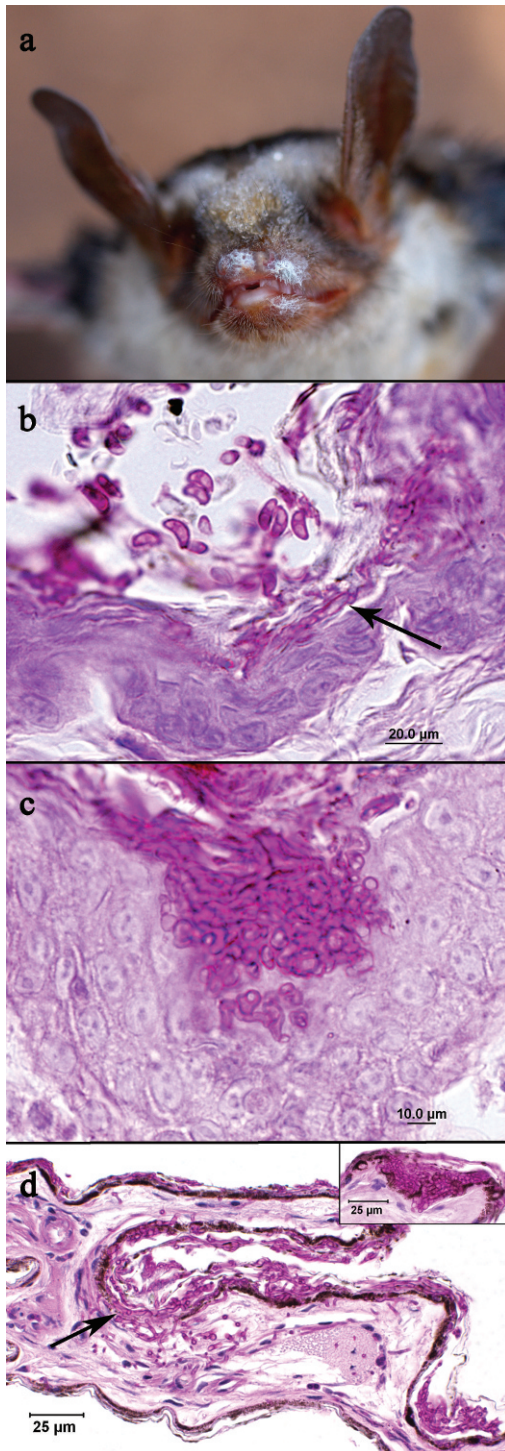


FIGURE 2. *Geomyces destructans* infection in a bat (*Myotis myotis*) from a hibernaculum in the Czech Republic, biopsied for histopathology, and comparison to the pathognomonic findings of

and showing visible fungal growth with brief illumination with a flashlight (Fig. 2a), was biopsied and euthanatized late in the hibernation period (4 April 2011). Clinical specimens collected from the muzzle using adhesive tape were positive for *G. destructans* conidiospores when examined by direct microscopy. The fungus was cultured on Sabouraud agar, and the isolate was genetically confirmed as *G. destructans* (EMBL-Bank accession number: HE588133). The sequence was identical to that previously reported from the Byčí skála cave (Martínková et al., 2010). Histopathologic findings on the skin of the muzzle were very similar to those observed in samples collected from bat cadavers as described above. Sections of the nasal skin and the wing membrane had large numbers of curved conidia associated with hyphae that were growing into the stratum corneum and through to the stratum basale (Fig. 2b). In contrast to the cadavers examined, dense aggregates of hyphae formed cupping erosions of the epidermis in the sampled euthanatized bat (Fig. 2c). Hyphae penetrated focally through the basement membrane to the dermis and deep into the hair follicles, also invading the associated sebaceous glands. There was lung congestion with large numbers of siderophages. There

←

white-nose syndrome (WNS) in the USA. (a) Male bat from the Byčí skála cave showing distinct fungal growth on the muzzle, around the nares as well as on the upper and lower lips. (b) Large numbers of curved conidia observed on the epidermis together with hyphae growing in stratum corneum and stratum basale (arrow). (c) A cuplike epidermal erosion in the nasal skin. (d) Section of wing membrane from a bat (*Myotis lucifugus*) with WNS collected in the USA. Inset shows typical cupping erosions diagnostic of WNS in the USA. The main image is a region of the same wing with superficial fungal colonization of the skin where it does not yet show the interface of dense fungi and cupping erosions but shows interruption of the basement membrane by fungal hyphae (arrow). Periodic acid-Schiff stain.

were no pathologic findings in spleen, kidneys, heart, or liver.

The histopathology in the skin of this greater mouse-eared bat from Byčí skála cave (Fig. 2c) fulfilled the criteria currently used to confirm WNS in North America (Meteyer et al., 2009). The localized areas of dense hyphae with a discrete interface where the fungus forms cup-shaped erosions was present in the bat from the Czech Republic collected in 2011, and these findings are the current gold standard for diagnosing WNS. Between these localized areas of erosion, colonization of the superficial keratin by the fungal hyphae is also present in wing membranes from bats with white-nose syndrome in the USA (Fig. 2d).

Our results confirm the presence of WNS in Europe and demonstrate that *G. destructans* infection in hibernating bats in Europe can be associated with sporadic deaths that may remain unrecognized in the hibernaculum. Mortality rates are low and, to date, have not affected the long-term population size of greater mouse-eared bats (Martínková et al., 2010). With the increase and extent of *G. destructans* found in hibernacula in the Czech Republic and Slovakia in 2010, monitoring bat populations in subsequent years is even more critical. Histopathology of bats with geomycosis was identified as one of the key research priorities in the field in Europe (Puechmaille et al., 2011a). Following confirmation of WNS in Europe, further comparisons between North American and European *G. destructans* infections can enhance the understanding of the pathogenesis of geomycosis in bats (Cryan et al., 2010).

Material from the Byčí skála cave was provided by Vlastislav Káňa in 2010. We thank Paul A. Racey, Maja Rütten, and four anonymous reviewers for helpful comments on the manuscript. This study was supported by the Ministry of Education, Youth and Sports of the Czech Republic (Projects MSM 6215712402, MSM 0021622416, LC06073). The research was

conducted in accordance with following permits: 35335/ENV/06-2793/620/06, 00163/MK/2009, S01389/MK/2008,142/2010, 169/2011.

LITERATURE CITED

- BLEHERT, D. S., A. C. HICKS, M. J. BEHR, C. U. METEYER, B. M. BERLOWSKI-ZIER, E. L. BUCKLES, J. T. H. COLEMAN, S. R. DARLING, A. GARGAS, R. NIVER, J. C. OKONIEWSKI, R. J. RUDD, AND W. B. STONE. 2009. Bat white-nose syndrome: An emerging fungal pathogen? *Science* 323: 227.
- CRYAN, P. M., C. U. METEYER, J. G. BOYLES, AND D. S. BLEHERT. 2010. Wing pathology of white-nose syndrome in bats suggests life-threatening disruption of physiology. *BMC Biology* 8: 135.
- FOLEY, J., D. CLIFFORD, K. CASTLE, P. CRYAN, AND R. S. OSTFELD. 2011. Investigating and managing the rapid emergence of white-nose syndrome, a novel, fatal, infectious disease of hibernating bats. *Conservation Biology* 25: 223–231.
- FRICK, W. F., J. F. POLLOCK, A. C. HICKS, K. E. LANGWIG, D. S. REYNOLDS, G. G. TURNER, C. M. BUTCHKOSKI, AND T. H. KUNZ. 2010. An emerging disease causes regional population collapse of a common North American bat species. *Science* 329: 679–682.
- KRAPP, F. 2001. *Handbuch der Säugetiere Europas*, Teil 1, Chiroptera 1. Aula Verlag, Wiebelsheim, Germany, 602 pp.
- MARTÍNKOVÁ, N., P. BAČKOR, T. BARTONIČKA, P. BLÁŽKOVÁ, J. ČERVENÝ, L. FALTEISEK, J. GAISLER, V. HANZAL, D. HORÁČEK, Z. HUBÁLEK, H. JAHLEKOVÁ, M. KOLAŘÍK, KORYTÁR, A. KUBÁTOVÁ, B. LEHOTSKÁ, R. LEHOTSKÝ, R. K. LUČAN, O. MÁJEK, J. MATĚJŮ, Z. ŘEHÁK, J. ŠAFÁŘ, P. TÁJEK, E. TKADLEC, M. UHRIN, J. WAGNER, D. WEINFURTOVÁ, J. ZIMA, J. ZUKAL, AND I. HORÁČEK. 2010. Increasing incidence of *Geomyces destructans* fungus in bats from the Czech Republic and Slovakia. *PLoS ONE* 5: e13853.
- METEYER, C. U., E. L. BUCKLES, D. S. BLEHERT, A. C. HICKS, D. E. GREEN, V. SHEARN-BOCHSLER, N. J. THOMAS, A. GARGAS, AND M. J. BEHR. 2009. Histopathologic criteria to confirm white-nose syndrome in bats. *Journal of Veterinary Diagnostics and Investigation* 21: 411–414.
- PUECHMAILLE, S. J., W. F. FRICK, T. H. KUNZ, P. A. RACEY, C. C. VOIGT, G. WIBBELT, AND E. C. TEELING. 2011a. White-nose syndrome: Is this emerging disease a threat to European bats? *Trends in Ecology and Evolution*, 26: 570–576.
- , G. WIBBELT, V. KORN, H. FULLER, F. FORGET, K. MÜHLDOERFER, A. KURTH, W. BOGDANOWICZ, C. BOREL, T. BOSCH, T. CHEREZY, M. DREBET, T. GÖRFÖL, A.-J. HAARSMA, F. HERHAUS, G. HAL-LART, M. HAMMER, C. JUNGSMANN, Y. LE BRIS, L. LUTSAR, M. MASING, B. MULKENS, K. PASSIOR, M. STARRACH, A. WOJTAŚZEWSKI, U. ZÖPHEL, AND E.

- C. TEELING. 2011b. Pan-European distribution of white-nose syndrome fungus (*Geomyces destructans*) not associated with mass mortality. PLoS ONE 6: e19167.
- WIBBELT, G., A. KURTH, D. HELLMANN, M. WEISHAAR, A. BARLOW, M. VEITH, J. PRÜGER, T. GÖRFÖL, L. GROSCHE, F. BONTADINA, U. ZÖPHEL, H.-P. SEIDL, P. M. CRYAN, AND D. S. BLEHERT. 2010. White-nose syndrome fungus (*Geomyces destructans*) in bats, Europe. Emerging Infectious Diseases 16: 1237–1243.
- Submitted for publication 31 December 2010.*
Accepted 12 September 2011.