

2011

## Physical Deformities and Subcutaneous Emphysema in a Population of House Sparrows

Ian R. K. Stewart

Daniel P. Wetzel

Margret I. Hatch

Follow this and additional works at: <https://digitalcommons.usf.edu/nabb>

---

### Recommended Citation

Stewart, Ian R. K.; Wetzel, Daniel P.; and Hatch, Margret I. (2011) "Physical Deformities and Subcutaneous Emphysema in a Population of House Sparrows," *North American Bird Bander*. Vol. 36 : Iss. 1 , Article 2. Available at: <https://digitalcommons.usf.edu/nabb/vol36/iss1/2>

This Article is brought to you for free and open access by the Searchable Ornithological Research Archive at Digital Commons @ University of South Florida. It has been accepted for inclusion in North American Bird Bander by an authorized editor of Digital Commons @ University of South Florida. For more information, please contact [digitalcommons@usf.edu](mailto:digitalcommons@usf.edu).

# Physical Deformities and Subcutaneous Emphysema in a Population of House Sparrows

**Ian R. K. Stewart**  
Department of Biology  
T.H. Morgan Building  
University of Kentucky  
Lexington, KY 40506

Corresponding author.

E-mail: itsacharliebrowncchristmas@hotmail.com

**Daniel P. Wetzel**  
Department of Biology  
T. H. Morgan Building  
University of Kentucky  
Lexington, KY 40506

**Margret I. Hatch**  
Department of Biology  
Penn State Worthington Scranton  
120 River View Drive  
Dunmore, PA 18512

## ABSTRACT

*Most reports of physical anomalies in wild birds are anecdotal and yet, reliable estimates of their frequency are key to understanding the strength of natural selection against them. We quantified the occurrence of aberrant morphology while banding a total of 7660 adult and nestling House Sparrows (*Passer domesticus*) in a long-term study population in central Kentucky. We found that 0.94% of all sparrows banded had some type of physical deformity and 1.2% of adult males had plumage anomalies. We also document two cases of subcutaneous emphysema in nestling sparrows. These data suggest that physical anomalies in this wild bird population are relatively rare, and that not all deformities are lethal.*

## INTRODUCTION

Natural selection is expected to act against individuals possessing morphological deformities since presumably, their ability to forage or reproduce is decreased, and their vulnerability to predation is increased (Darwin 1859). Nevertheless, there are numerous anecdotal reports of such deformities in wild birds (e.g., Arendt and Arendt 1986; Thompson and Terkanian 1991; Robbins and Pokras 1995), suggesting that the strength of selection against certain imperfections may be exaggerated. However, it is difficult to estimate how frequent abnormalities are in natural populations of wild birds from isolated reports. Even estimates based on observations of many unmarked birds (e.g., Sharp and Neill 1979) are prone to error because affected individuals may be

counted twice and the total number of individuals observed can only be estimated. Systematic examination of a large number of banded birds provides a more reliable estimate of abnormalities. For instance, Hicks (1934) performed a meticulous study of abnormalities in over 10,000 European Starlings (*Sturnus vulgaris*) banded in Ohio and found that 5.4% had some form of morphological anomaly, although most of the cases were merely missing toenails.

Our objective was to quantify systematically physical anomalies in a wild bird population, and where possible, recapture abnormal individuals to ascertain whether these conditions are permanent or transient. We collected morphological data from a nest box population of House Sparrows (*Passer domesticus*) which we have been studying continuously since 1992. We report the frequency of various physical deformities or aberrant features of the birds we banded and describe in detail two cases of subcutaneous emphysema we encountered in nestling sparrows.

## METHODS

We monitored a nest box population of House Sparrows at the University of Kentucky's Agricultural Experimental Research Station located just north of Lexington, KY (38°06' N, 84°29' W) from 1992 to 2009. The station consists of 5 km<sup>2</sup> of agricultural and pastoral fields and contains several barns used for equine stables and equipment storage. Nest boxes were erected on the outside of

several of these barns. The number of barns with nest boxes and the number of nest boxes per barn varied from year to year, but typically consisted of four barns with 10 to 20 nest boxes on each. Adult and juvenile House Sparrows were captured using mist nets or seed-baited cage traps and banded with a USFWS aluminum band and a unique combination of plastic color bands. Nestlings were banded approximately 10 days after hatching. We recorded standard morphological measurements of all banded birds. While banding birds, we noted any physical deformity or anomalous feature. In total, 7,660 individual birds were banded during 1996-2005 and 2007-2009 (837 adult males, 686 adult females and 6,137 nestlings).

## RESULTS

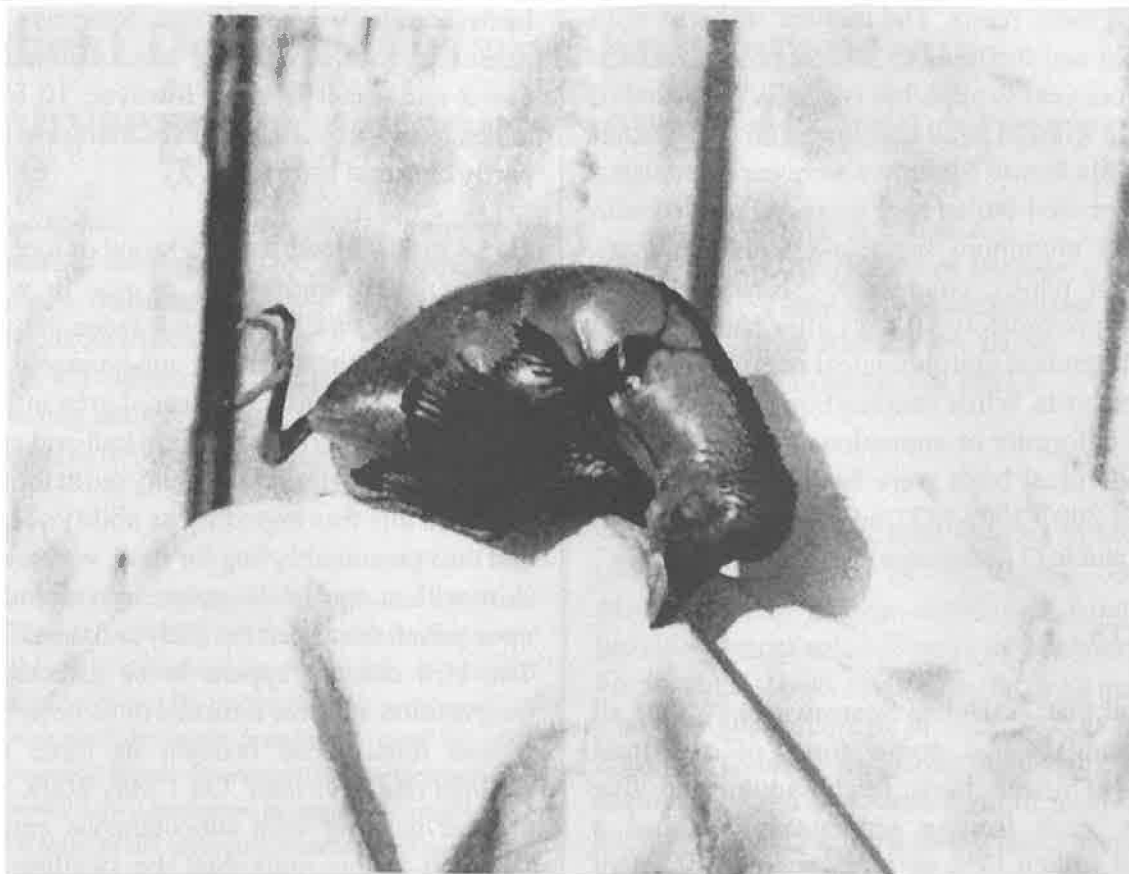
We found that 72 House Sparrows (0.94% of all birds handled) had some form of structural anomaly. Thirteen birds (eight adults and five nestlings, each from a separate brood) had a deformed bill (0.17% of birds handled). One of these nestlings was missing its upper bill entirely and did not survive to fledging. Thirty-six birds had some form of leg deformity (0.47% of birds handled). Two adults (one male, one female) had a healed broken femur. One adult had an ulcerous swelling on one leg and one nestling had two stunted and deformed legs. A further 32 sparrows (10 adults and 22 nestlings, each from separate broods) had one deformed leg, which was either a bent or twisted bone or a clubbed foot. The deformities were significantly more common on the right leg than the left (23 right leg deformities versus nine left leg deformities,  $\chi^2=6.13$ ,  $P=0.01$ ). Seven adults were blind in one eye (0.45% of adult birds handled). Two males were missing one eye, including one who was caught by hand as he sat on a fence. The other five adults had lost the use of one eye due to severe conjunctivitis (three with a swollen, puffy eye indicative of a current infection, and two with a dry crust which had formed over their eye, indicative of an older infection). Three adults were bald on the rear half of their head, and all three nestlings in one brood were bald (0.08% of

birds handled). Male House Sparrows typically possess a distinctive bib of black feathers on their throat and upper breast. However, 10 of the 837 males handled (1.2%) had bibs that were wholly or partly chestnut brown.

On 28 Jun 1999, we found a brood of four nestlings approximately eight days of age in which one nestling was swollen to about twice the size of its siblings, consistent with subcutaneous emphysema. Its dorsal surface appeared to be inflated with air which had stretched its skin taut and caused the head to bow and the legs to splay out at the side (Fig. 1). Since this was impeding its ability to sit upright and thus presumably beg for food, we punctured its skin with a sterile 26-gauge hypodermic needle upon which the air left the body and the skin sagged. The bird did not appear to be affected by this intervention and was returned to its nest. However, it was found dead beneath its three surviving siblings two days later. On 1 May 2009, we found another nestling with subcutaneous emphysema, although in this individual the swelling was less pronounced and we did not attempt to evacuate the air from the bird. The nestling was still swollen with air when it was banded three days later, but it fledged along with its three siblings on 14 May 2009. The nestling was captured as a juvenile 11 days later but showed no symptoms of emphysema. It was recruited into the breeding population the following summer as an adult female and was recaptured but had no sign of emphysema.

## DISCUSSION

**Physical anomalies.** We handled several House Sparrows with deformed or damaged bills or legs. Aberrant bills were mostly twisted or cracked, or had one grossly elongated or misshapen mandible. Overall, 0.2% of House Sparrows had a bill deformity, which is similar to the frequency recorded in European Starlings banded in Ohio (Hicks 1934) though lower than the frequency in North American blackbirds observed at a winter feeding station (1.2%, Sharp and Neill 1979) and considerably lower than that found in Black-capped



**Fig. 1. Nestling House Sparrow with severe subcutaneous emphysema. A large blood clot can be seen on the side of the neck.**

Chickadees (*Poecile atricapillus*) (6.5%) and Northwestern Crows (*Corvus caurinus*) as part of an apparent recent epizootic in Alaska (16.9%; Handel et al. 2010; van Hemert and Handel 2010).

Leg deformities ranged from relatively subtle abnormalities likely due to developmental problems to more severe injuries which are more likely to have been caused by a predator. Most leg deformities were represented by a bent or twisted tarsus, although an adult male and female caught during the breeding season each had a broken femur. Despite this handicap, the male paired and bred successfully. The female paired but only laid infertile eggs, presumably because the leg injury prevented her from achieving the correct copulatory posture (Stewart 2003). Deformities were significantly more common on the right leg than the left leg, for unknown reasons. Blake (1957) also observed a greater proportion of injuries to the right leg when handling Jamaican birds, which was

attributed to a systematic error in the banding process. This is unlikely to be the explanation for the bias seen in our population, however, since the majority (27/32) of the birds with injuries to one leg were unbanded when they were first processed. We have found no other reports of biases in limb injury in birds.

Seven adults were blind in one eye (0.45% of adults handled), which in five cases was clearly caused by disease (conjunctivitis). The other two one-eyed birds were both adult males and showed evidence of damage to their empty eye socket. These eyes were probably lost during the highly aggressive fights over nest sites which occasionally take place between male House Sparrows, where one male pins down another and pecks at his eyes (pers. obser.). The frequency of one-eyed House Sparrows was very similar to that reported in European Starlings (0.46%, Hicks 1934). Intuitively, birds with one eye should be very prone to

predation. However, the injuries to the eye socket observed in two male sparrows did not appear recent, suggesting that birds which lose an eye are not depredated immediately.

Baldness was uncommon, with only six bald birds encountered (out of 7,660 handled). There are many anecdotal reports of baldness in wild birds, although a general explanation is currently lacking. Baldness has been ascribed to a variety of circumstances, most commonly dietary deficiency, stress during molt, or an infestation of sarcoptic mites similar to those responsible for mange in mammals (McDonald 1963). The latter possibility would account for the fact that three of the bald birds were nestlings from the same brood. Two of the three bald adults were recaptured in subsequent breeding seasons but their heads were fully feathered, suggesting that baldness does not have a strong genetic component.

We found around 1% of males had breast patches which were colored a metallic chestnut brown instead of the usual black. The blackness of the breast feathers of male House Sparrows is due to the presence of eumelanin, one of the two classes of the pigment melanin (McGraw 2006). The second class of melanin pigments are the phaeomelanins, which are responsible for the appearance of brown feathers and were presumably present in the breast feathers of these aberrant males. Melanin production may become biased toward phaeomelanin rather than eumelanin if there is a reduction in the level or activity of the enzyme tyrosinase, which is essential for the initial oxidation of tyrosine, the amino acid precursor to all melanins (see McGraw 2006 for a review). Three of these males were recaptured in more than one molt year and had brown bibs in both, suggesting that the factors responsible for the bias towards phaeomelanin production were not associated with one unusually stressful molt but may have a genetic component.

**Subcutaneous emphysema.** Subcutaneous emphysema results from traumatic injury by a blunt

or sharp object and is caused by either air leaking from damaged air sacs (Gibbons and Horton 2000) or by anaerobic bacteria (typically *Clostridium* sp.) colonizing the layer beneath the skin following a lesion (Nievas et al. 2007). There are very few records of subcutaneous emphysema in wild birds. Middleton (1951) reported an adult American Tree Sparrow (*Spizella arborea*) swollen to twice its normal size due to emphysema, which survived but had to be lanced four times before it stopped accumulating air. Gochfeld (1974) found 18 cases among over 11,000 nestlings of five coastal seabird species handled on Long Island, NY (0.16%), all of which survived after treatment for air evacuation. The relatively high frequency of subcutaneous emphysema among nestlings in these dense seabird colonies is likely due to frequent attacks by territorial adults which peck the chicks (Gochfeld 1974). The House Sparrow nestling we found with severe emphysema had a conspicuous hematoma at the base of its wing (Fig. 1), which was likely the result of an injury, since the other members of the brood also showed signs of being pecked. The injury probably represented an attempt at infanticide by another male House Sparrow, since unpaired males occasionally try to take over active nests of other males by pecking their nestlings to death (Anderson 2006, pers. obser.). No other published cases of subcutaneous emphysema in House Sparrows exist, but another long-term banding program of House Sparrows in North America found a similarly low incidence (four cases out of 4,710 nestlings banded, 0.08%; P.E. Lowther, per. com.) as in our study population (0.03%).

In summary, our study found that physical deformities were rare in House Sparrows. While some of these deformities are obviously permanent (e.g. loss of an eye), some plumage abnormalities appear to be maintained across molts (e.g. phaeomelanistic breast plumage) while others are transient (e.g. baldness). Given that such deformities and abnormalities likely have multiple origins (see Handel et al. 2010), we stress the need for further studies involving the recapture of affected



individuals within the same population in order to distinguish abnormalities with a developmental basis from those caused by environmental agents, such as disease.

## ACKNOWLEDGMENTS

We thank D.F. Westneat for access to the study population, the staff of the field station for allowing us to erect and census nest boxes, and the numerous field assistants that have helped collect these data over the years. We thank C.R. Blem, P.E. Lowther, G. Ritchison and two anonymous referees for helpful comments on an earlier version of this manuscript and P.E. Lowther for providing data.

## LITERATURE CITED

- Anderson, T.R. 2006. Biology of the ubiquitous House Sparrow: from genes to populations. Oxford University Press, New York, NY.
- Arendt, W.J. and A.I. Arendt. 1986. Bill deformity in a Pearly-eyed Thrasher from Montserrat, West Indies. *North American Bird Bander* 11:51-52.
- Blake, C.H. 1957. Diseases and injuries of Jamaican birds. *Bird-Banding* 28:157-159.
- Darwin, C.R. 1859. The origin of species by means of natural selection, or the preservation of favoured races in the struggle for life. John Murray, London, UK.
- Gibbons, P.M. and S. Horton. 2000. What is your diagnosis? *Journal Avian Medical Surgery* 14:60-64.
- Gochfeld, M. 1974. Prevalence of subcutaneous emphysema in young terns, skimmers and gulls. *Journal Wildlife Diseases* 10:115-120.
- Handel, C.M., L.M. Pajot, S.M. Matsuoka, C. van Hemert, J. Terenzi, S.L. Talbot, D.M. Mulcahy, C.U. Meteyer, and K.A. Trust. 2010. Epizootic of beak deformities among wild birds in Alaska: an emerging disease in North America? *Auk* 127:882-898.
- Hicks, L.E. 1934. Individual and sexual variations in the European Starling. *Bird-Banding* 5:103-118.
- McDonald, J.W. 1963. Blue Tit with acarine mange. *British Birds* 56:221.
- McGraw, K.J. 2006. Mechanics of melanin-based coloration. Pgs. 243-294 in *Bird coloration*, vol. 1 (G.E. Hill and K.J. McGraw, eds). Harvard University Press, Cambridge, MA.
- Middleton, R.J. 1951. A sick Tree Sparrow, *Spizella a. arborea*. *Auk* 68:111-112.
- Nievas, V.F., G.A. Leotta, and G.B. Vigo. 2007. Subcutaneous clostridial infection in Adelle Penguins in Hope Bay, Antarctica. *Polar Biology* 30:249-252.
- Robbins, P.K. and M. Pokras. 1995. Congenital anomalies in a Mourning Dove (*Zenaida macroura*). *Journal Avian Medical Surgery* 9:182-184.
- Sharp, M.S. and R.L. Neill. 1979. Physical deformities in a population of wintering blackbirds. *Condor* 81:427-430.
- Stewart, I.R.K. 2003. Male House Sparrow *Passer domesticus* copulates successfully despite broken leg. *Ornis Svecica* 12:212-214.
- Thompson, C.W. and B.A. Terkanian. 1991. Abnormally long bill in a young Curve-billed Thrasher. *Journal Field Ornithology* 62:157-161.
- van Hemert, C. and C.M. Handel. 2010. Beak deformities in Northwestern Crows: evidence of a multispecies epizootic. *Auk* 127:746-751.