

October 2017

External auditory exostoses and hearing loss in the Shanidar 1 Neandertal

Erik Trinkaus

Sebastian Villotte

Follow this and additional works at: https://digitalcommons.usf.edu/kip_articles

Recommended Citation

Trinkaus, Erik and Villotte, Sebastian, "External auditory exostoses and hearing loss in the Shanidar 1 Neandertal" (2017). *KIP Articles*. 1919.
https://digitalcommons.usf.edu/kip_articles/1919

This Article is brought to you for free and open access by the KIP Research Publications at Digital Commons @ University of South Florida. It has been accepted for inclusion in KIP Articles by an authorized administrator of Digital Commons @ University of South Florida. For more information, please contact digitalcommons@usf.edu.

RESEARCH ARTICLE

External auditory exostoses and hearing loss in the Shanidar 1 Neandertal

Erik Trinkaus^{1*}, Sébastien Villotte²

1 Department of Anthropology, Washington University, Saint Louis, Missouri, United States of America, **2** UMR5199 PACEA, Université de Bordeaux–CNRS, Bâtiment B8, Allée Geoffroy Saint Hilaire, Pessac cedex, France

☯ These authors contributed equally to this work.

* trinkaus@wustl.edu



OPEN ACCESS

Citation: Trinkaus E, Villotte S (2017) External auditory exostoses and hearing loss in the Shanidar 1 Neandertal. PLoS ONE 12(10): e0186684. <https://doi.org/10.1371/journal.pone.0186684>

Editor: Karen Rosenberg, University of Delaware, UNITED STATES

Received: June 8, 2017

Accepted: October 5, 2017

Published: October 20, 2017

Copyright: © 2017 Trinkaus, Villotte. This is an open access article distributed under the terms of the [Creative Commons Attribution License](https://creativecommons.org/licenses/by/4.0/), which permits unrestricted use, distribution, and reproduction in any medium, provided the original author and source are credited.

Data Availability Statement: All relevant data are within the paper and its Supporting Information files.

Funding: This work was supported by National Science Foundation (US) grant NSF BNS76-14344 (Biological Anthropology Program) (https://www.nsf.gov/funding/pgm_summ.jsp?pims_id=5407) to Erik Trinkaus; National Science Foundation (US) grant NSF BNS80-04578 (Biological Anthropology Program) (https://www.nsf.gov/funding/pgm_summ.jsp?pims_id=5407) to Erik Trinkaus. The funder had no role in study design, data collection

Abstract

The Late Pleistocene Shanidar 1 older adult male Neandertal is known for the crushing fracture of his left orbit with a probable reduction in vision, the loss of his right forearm and hand, and evidence of an abnormal gait, as well as probable diffuse idiopathic skeletal hyperostosis. He also exhibits advanced external auditory exostoses in his left auditory meatus and larger ones with complete bridging across the porus in the right meatus (both Grade 3). These growths indicate at least unilateral conductive hearing (CHL) loss, a serious sensory deprivation for a Pleistocene hunter-gatherer. This condition joins the meatal atresia of the Middle Pleistocene Atapuerca-SH Cr.4 in providing evidence of survival with conductive hearing loss (and hence serious sensory deprivation) among these Pleistocene humans. The presence of CHL in these fossils thereby reinforces the paleobiological and archeological evidence for supporting social matrices among these Pleistocene foraging peoples.

Introduction

Paleopathological assessments of Pleistocene human remains have increasingly identified a suite of substantial and/or systemic developmental and degenerative abnormalities among the remains, in addition to an abundance of minor traumatic and oral lesions [1–5]. In addition, several abnormalities have been identified which would have impaired the normal functioning of the individuals, especially in the context of mobile Pleistocene foraging populations [6–10]. These alterations have suggested that the levels of social support present among recent humans (beyond the mother-child dyad) were present since the Early Pleistocene [6,9–11]. These inferences have implications for the levels of social integration and complexity among these non-modern members of the genus *Homo*.

In these assessments and inferences, however, there has been little consideration of impairments of the basic senses, ones which would have limited the abilities of the individuals to effectively perceive and respond appropriately to their natural and social environments. The only possible examples are post-traumatic unilateral ocular alterations in the Shanidar 1 Neandertal [6] and reduced conductive hearing in the Middle Pleistocene Atapuerca-SH Cr.4 from auditory exostoses [12]. The presence and degree of development of external auditory

and analysis, decision to publish, or preparation of the manuscript.

Competing interests: The authors have declared that no competing interests exist.

exostoses in the Shanidar 1 cranium may provide an additional, and substantial, case of such sensory impairment among these Pleistocene hunting-gathering populations.

External auditory exostoses (EAE) are bony growths into the auditory canal from the tympanic and/or squamous walls of the external auditory meatus and the margins of the auditory porus [13,14]. They vary from small rounded protrusions to processes that largely fill the meatus, are usually limited to the lateral opening of the canal (the porus), but may extend medially to the area of the tympanic membrane. They normally do not involve or develop from the tympanosquamous or tympanomastoid sutures; such sutural protrusions are osteomata, or benign neoplasms, which normally occur laterally within the meatus, are less frequent and are often solitary [14,15] (S3 Text). Either one can reduce the lumen of the auditory meatus.

EAE have been extensively documented in clinical settings and Holocene skeletal samples (see reviews in [13,16,17]). Their etiology in individual cases is not always apparent, but in general they are associated with prolonged exposure of the auditory canal to cold water (for a review, see [16]). They occur in elevated frequencies among modern participants in cold water sports (hence references to “swimmer’s/surfer’s ear”) (e.g. [18–24]). EAE have also been extensively recorded in Holocene skeletal samples, with particular attention focused on samples of people frequently engaged in aquatic resource exploitation (e.g. [17,25–34]).

EAE presence has been noted in a couple of Middle Pleistocene humans [12,35], several Late Pleistocene archaic humans [36–39], and a few early modern humans [40], and their absence has been noted in a few other Pleistocene humans [41–43]. Yet, the only discussion of the effects of such changes in the auditory canals among these Pleistocene humans has been the mention of deafness in the Atapuerca-SH Cr.4 [12]. The pronounced ones of the Shanidar 1 Neandertal, however, may provide further insight into these aspects of Pleistocene humans.

Materials and methods

The ≈ 50 ka BP Shanidar 1 Neandertal cranium [6,44] (S1 Text) was analyzed visually with low magnification assessment of the intact right and left external auditory meatus in the Iraq Museum, Baghdad in 1976–78. It is part of the largely complete skeleton of an adult (40–50 years old, based on his pubic symphysis and dental wear comparisons to the histologically aged Shanidar 2 to 6) male (pelvically sexed based on the greater sciatic notch) [6,45]. Cranial radiography was not available in the Iraq Museum, and reanalysis since then has not been feasible. Observations are therefore based on the externally visible configurations of the auditory porus and lateral meatus (Fig 1).

The degree of development of the EAE is scored using an ordinal scale of Grade 0 (absence of EAE) to Grade 3 (large EAE that largely block the meatus) (Grade 1: $<1/3$; Grade 2: $1/3$ – $2/3$; Grade 3: $>2/3$) [19,25,26] (see also [13]). Similar observations are provided for four other Neandertals with EAE, the younger adult Spy 1 and Tabun 1 and the modestly older La Chapelle-aux-Saints 1 partial skeletons, plus the Krapina 39.1 isolated mature temporal bone (S2 Text).

The Shanidar 1 external auditory meatus

Both of the external auditory meatus (EAM) of Shanidar 1 are well preserved; inferiorly the tympanic and adjacent portions of the temporal bone present little of note (Fig 1, S1 Text). The tympanic bones are complete, fully fused to the squamous and petrous portions, with complete closure of the foramina of Huschke.

The left porus (Fig 1A) has a normal anterior portion of the tympanic bone, that leads into a thick and inferiorly protruding tympanic bone against the mastoid process. There are no alterations of the adjacent squamous and mastoid bone. There is a large growth protruding laterally and anteriorly into the porus along all of the posterior side of the porus. It is on the

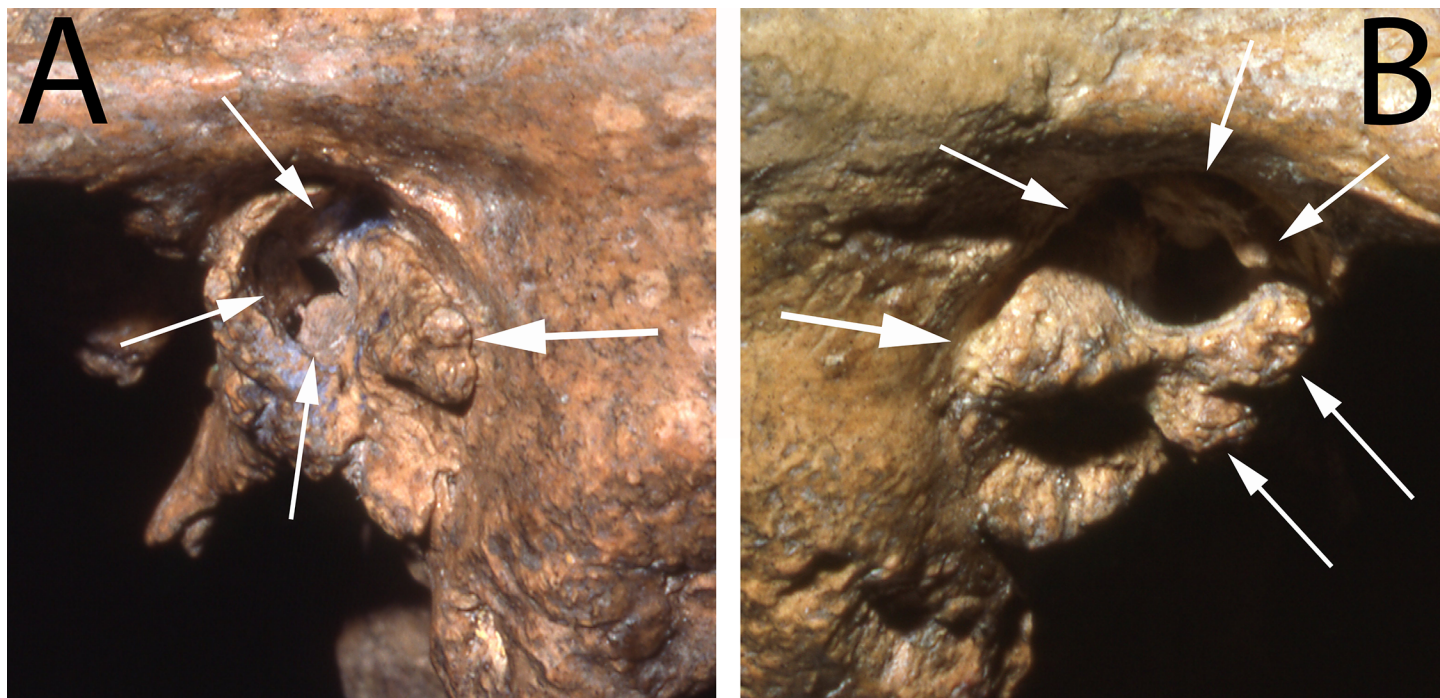


Fig 1. The temporal bones of Shanidar 1. A and B: lateral views of the left and right external auditory meatus illustrating the large external auditory exostoses, especially the bridging ones on the right side. The arrows point to the exostosis growths described in the text.

<https://doi.org/10.1371/journal.pone.0186684.g001>

lateral surface of the posterosuperior tympanic bone, but it extends anterosuperiorly into the porus and more medially into the meatus. Superiorly, this exostosis is very close to a small exostosis within the meatus, one which grew posteroinferiorly from the superior portion of the tympanic bone, immediately below the tympanosquamous suture. In addition, deeper within the meatus but laterally visible, there is a rounded protrusion extending close to the middle of the canal from the posteroinferior tympanic bone and a smaller one deep on the anterior tympanic bone. Together these growths provide the Shanidar 1 left EAM with a Grade 3 score. The lateral opening of the canal was reduced to a very small one in the middle of its anterior portion.

The right external auditory meatus and porus of Shanidar 1 (Fig 1B) has a more pronounced EAE development than the left one. The inferolateral margin of the tympanic bone is normal, as are the surrounding squamous and mastoid portions. Protruding laterally and especially anteriorly from the mid-posterior tympanic bone is a large and bulbous exostosis, the major portion of which extends to the middle of the meatus. Its posterior portion continues superiorly to where it approaches the superior extent of the anterior tympanic bone. But across the middle of the opening, the large exostosis narrows and then connects to a pair of more modest exostoses, which extend laterally and posteriorly from the mid-anterior tympanic bone.

This combination of right meatal growths completely blocks the middle of the porus, leaving only small openings anterosuperiorly and posteroinferiorly. They are then joined by a small protuberance within the meatus projecting inferiorly from the superior-most anterior tympanic bone. These large EAE, and especially the bridging of them across the middle of the porus, provide the Shanidar 1 right auditory canal with a serious Grade 3 score.

Data on the shapes of the more medial canal are not fully available; the visible EAE may extend medially along the auditory canals, as is indicated by the small ones within each meatus.

The medial canals adjacent to the area of the tympanic membrane are nonetheless conservatively assumed to be normal.

The external auditory meatus of this moderately older Neandertal therefore present slightly different patterns of abnormalities. The left one approximates the marked patterns occasionally encountered in recent humans. The right one extends to the upper end of the four-part ordinal scale.

Discussion

Shanidar 1

The degree of development of the Shanidar 1 EAE is associated with conductive hearing loss (CHL) in extant humans [19,21,23,24,46–49]. Most EAE are located laterally in the auditory canal; as a result, usually they do not impinge directly on the tympanic membrane. Yet, they may extend medially, causing stenosis of the canal and associated CHL [50]. Even though individuals vary in their rates of production of cerumen and responses to irritation of the auditory canal, large (Grade 3) EAE would make it extremely difficult for the normal irrigation of the ear canal to cleanse the cerumen and exogenous debris from the canal [14,47,51]. The accumulated material, in combination with the exostoses, would then reduce both the sound transmission through the ear canal and the ability of the tympanic membrane to transmit the sound waves to the middle ear [52,53]. Impacted cerumen and exogenous material in the canal is therefore a common cause of CHL in recent humans.

The left meatus of Shanidar 1 is likely to have accumulated sufficient material to produce CHL, given its large posterior exostoses across at least half of the lateral opening. The right one, however, would have led to the presence of cerumen and other debris behind the bony bridging that connects the anterior and posterior exostoses. It would have been essentially impossible for Shanidar 1 to maintain a sufficiently clear canal for adequate sound transmission. He would therefore have been effectively deaf in his right ear, and he likely had at least partial CHL in the left ear.

Consequently, Shanidar 1 appears to have had an advanced degree of unilateral conductive hearing loss and reduced hearing acuity on both sides. In addition to a general reduction in hearing acuity, unilateral CHL limits one's ability to discern the signal from background noise and to locate sounds in space. Among modern urban children it is associated with varying degrees of reduced academic progress [53], and hearing loss in living adults is associated with difficulties in communication, information exchange and social interactions, decreased mental and physical function, isolation, and psychological disorders [54–56].

In addition to a reduced effectiveness in communication and coordinated social activities (among these fully linguistic Paleolithic foragers [57–59]), it would have had more direct consequences. Hearing acuity is related to hunting effectiveness among recent human foragers [60]. Hearing is an important component of learning lithic technology [61]. Well developed auditory acuity is especially important in providing feedback during multistep lithic reduction that requires the fashioning of both sequential striking platforms and the desired tool [61]; this requirement applies to Acheulian bifaces and subsequent lithic procedures. CHL would also have made the individual vulnerable to medium to large carnivores, predators that were ubiquitous in Late Pleistocene Eurasia [62], the Zagros Mountains [63] and at Shanidar Cave [64].

Shanidar 1 also experienced a suite of other degenerative difficulties [6,44,65] (S1 Text). He is best known for his withered right shoulder and arm, that was little more than a weakened stump extending to just proximal of the elbow; it was most likely amputated above the elbow, possibly after a non-union fracture and associated atrophy. He had a laterally crushing fracture of the left orbit (probably altering and/or reducing vision). He experienced right genua and

pedal trauma and osteoarthritis producing an abnormal gait (reflected in right talar remodeling and left tibiofibular posterior bowing), thereby impairing his landscape mobility and agility. And there is evidence of probable hyperostotic disease (DISH), which is associated with muscular tendinosis and reduced back and appendicular ranges of motion. It is therefore in addition to these degenerative conditions that any degree of hearing loss would have compounded the limited abilities of this individual to function.

Other Pleistocene human external auditory exostoses

As noted above, external auditory exostoses have been observed in other Pleistocene humans, but most of them are modest in size. Four other Neandertals, La Chapelle-aux-Saints 1, Krapina 39.1, Spy 1 and Tabun 1, exhibit large EAE, ones which would be scored as Grade 2 [S2 Text]. Their bony growths are less likely by themselves to have produced advanced CHL, but they probably reduced the abilities of those individuals to cleanse their auditory canals and hence maintain auditory acuity.

In addition, the Middle Pleistocene (≈ 430 ka) Atapuerca-SH Cr.4 [66] developed bilateral Grade 2 EAE, but it resulted in atresia of the auditory canal [12]. This narrowing of the canal is usually a rare congenital condition, occurring in 1 out of 10,000–20,000 individuals, most often unilaterally [14,67,68]. The condition in Atapuerca-SH Cr.4 appears to be the result of the EAE extending medially and almost entirely blocking the canals. The degree of CHL associated with this degree of aural atresia would be moderate to severe [53], and it would therefore have had consequences similar to those for Shanidar 1.

Pleistocene human social support

The advanced EAE of Shanidar 1, as well as that of Atapuerca-SH Cr.4, and the consequent CHL raise the question of social assistance among Pleistocene archaic *Homo*. The presence of social support among non-modern Pleistocene humans, as noted above, has been inferred for a number of Pleistocene individuals with substantial abnormalities and varying degrees of loss of function (e.g. [6,7,9–11,44] (see [69])). Comparisons with non-captive non-human primates, however, have questioned whether some of these abnormalities would have been sufficient to require social support in order for the individual to survive [70–72] (note, however, that the survival of macaques with congenital limb deformities documented by Turner et al. [72] is not relevant, because they were provisioned and hence had “social support”). For example, apes born with congenital disorders are sometimes maintained by their mothers for extended periods of time through infancy [73]. Apes lacking one eye appear to manage effectively in the wild [74]. Apes who have lost a hand or a foot (as in a snare) are able to climb and forage, although less effectively than their conspecifics [75,76]. And wild-shot primates are known (if rare) with up to two thirds of the dentition lost antemortem [10,77].

The non-human primate examples provided here are relevant for inferences regarding several Neandertals with partial loss of function. For example, the survival of the developmentally abnormal of the Pech-de-l’Azé 1 Neandertal child [78] should represent maternal support of an affected offspring. The apparent unilateral impaired vision of Shanidar 1, by itself, may not have limited his abilities. The upper limb fractures of Feldhofer 1 and Krapina 180 and 188.8 [79,80], as well as the right arm and shoulder of Shanidar 1, limited or severely reduced the utilities of the affected arms; yet, by themselves they would have implied only partial loss of foraging ability. The extensive antemortem tooth loss of La Chapelle-aux-Saints 1, and the less pronounced losses of Shanidar 4 and 5 [6,81], need not have limited their abilities to ingest food. However, the Aubesier 11 Neandertal and the Early Pleistocene Dmanisi D3444/D3900 experienced extensive antemortem tooth loss and (more importantly) pervasive infectious

alteration of the maxilla and/or mandible [9,10]; they are joined by the Guattari 1 edentulous cranium with palatomaxillary inflammation [82]. Considerations of these fossils that only addressed the tooth loss [70,71] missed the point; these individuals had severely impaired oral tissues and not merely a loss of teeth. In addition, as emphasized by Hublin [69], the long term persistence of the Middle Pleistocene Atapuerca-SH Cr.14 and Salé 1 with substantial congenital abnormalities (cranial synostosis and torticollis, respectively) [7,11] imply care beyond the infantile maternal support evident among non-human primates.

In this context, the conductive hearing loss (CHL) of Shanidar 1 and Atapuerca-SH Cr.4 join several other Pleistocene archaic *Homo* individuals (if not all of the ones that have been invoked in the past) in indicating some level of social support. Moreover, although one could discuss the degrees to which support would have been necessary for the survival of those individuals with degenerating mastication or cranial developmental defects, an individual with advanced CHL would have been highly vulnerable alone in a Pleistocene foraging context (see above). For Shanidar 1, the CHL was associated with loss of function in other aspects of his biology, all of which would have compounded his need for support, even if some of the individual deficiencies by themselves would not have required such assistance.

The inferred presence of social support among at least the Neandertals should not be surprising. There is abundant evidence of intentional burial of the dead [83], even if not all of the known remains derive from such burials. Explicit mortuary practice reflects, ultimately, the presence of social cohesion, social roles, and hence mutual support [84,85], such as would have led to the caring of the impaired. There are items of personal decoration [86–88] and the use of pigments [89,90], which are modifications of one's visual persona and hence a reflection of social identity manipulation and social cohesion. A number of Neandertal sites exhibit distinct spatial organization (e.g. [91–94]), reflecting coordinated use of the occupied space. There is evidence for division of labor by age and sex among them [95,96], reflecting the social integration of different roles. Moreover, whatever the Late Pleistocene human population dynamics might have been [97,98], it is increasingly apparent that the behavioral differences between the Neandertals and their modern human contemporaries and successors were modest [99–101].

Conclusion

The Shanidar 1 Neandertal, in addition to his other traumatic and degenerative lesions, developed advanced external auditory exostoses, largely blocking the meatus on the left side and bridging across the auditory porus on the right side. Although a normal bony growth in the context of irritation of the external auditory canal, the extent of exostosis development in Shanidar 1 indicates a marked degree of conductive hearing loss. It joins the Middle Pleistocene Atapuerca-SH Cr.4, with its auditory atresia and associated deafness, in indicating survival of these sensorily impaired archaic humans despite the rigors and dangers of a Middle-to-Late Pleistocene foraging existence. A substantial degree of social support, especially given Shanidar 1's plethora of other impairments, is indicated.

Supporting information

S1 Text. The Shanidar 1 abnormalities

(PDF)

S2 Text. Neandertal external auditory exostoses.

(PDF)

S3 Text. Differential diagnosis.

(PDF)

Acknowledgments

Analysis of Shanidar 1 in the Iraq Museum was possible through the courtesy of I. Salman, M. S. al-Damirji and F. Rashid, assisted by R.S. Solecki, the late T.D. Stewart, and D. George. A. Balzeau/MNHN provided the La Chapelle-aux-Saints CT data.

Author Contributions

Conceptualization: Erik Trinkaus, Sébastien Villotte.

Data curation: Erik Trinkaus.

Methodology: Sébastien Villotte.

Writing – original draft: Erik Trinkaus.

Writing – review & editing: Sébastien Villotte.

References

1. Wu XJ, Schepartz LA, Liu W, Trinkaus E. Antemortem trauma and survival in the Late Middle Pleistocene human cranium from Maba, south China. *Proc Natl Acad Sci USA*. 2011; 108(49):19558–62. <https://doi.org/10.1073/pnas.1117113108> PMID: 22106311
2. Lacy SA. Oral Health and its Implications in Late Pleistocene Western Eurasian Humans [dissertation]. Saint Louis: Washington University; 2014.
3. Trinkaus E, Buzhilova AP, Mednikova MB, Dobrovolskaya MV. The People of Sunghir. New York: Oxford University Press; 2014.
4. Martín-Francés L. Revisión y Estudio des las Manifestaciones Paleopatológicas en los Homininos del Plio-Pleistoceno, con Especial Referencia a Algunos Fósiles de la Sierra de Atapuerca [dissertation]. Alacalá: Universidad de Alcalá; 2015.
5. Wu XJ, Xing S, Trinkaus E. An enlarged parietal foramen in the late archaic Xujiayao 11 neurocranium from northern China, and rare anomalies among Pleistocene *Homo*. *PLoS ONE*. 2013; 8(3):e59587. <https://doi.org/10.1371/journal.pone.0059587> PMID: 23527224
6. Trinkaus E. The Shanidar Neandertals. New York: Academic; 1983.
7. Hublin JJ. L'émergence des Homo sapiens archaïques: Afrique du Nord-Ouest et Europe Occidentale [dissertation]. Bordeaux: Université de Bordeaux I; 1991.
8. Spoor F, Stringer CB, Zonneveld F. Rare temporal bone pathology of the Singa calvaria from Sudan. *Am J Phys Anthropol*. 1998; 107(1):41–50. [https://doi.org/10.1002/\(SICI\)1096-8644\(199809\)107:1<41::AID-AJPA4>3.0.CO;2-G](https://doi.org/10.1002/(SICI)1096-8644(199809)107:1<41::AID-AJPA4>3.0.CO;2-G) PMID: 9740300
9. Lordkipanidze D, Vekua A, Ferring R, Rightmire GP, Agusti J, Kiladze G, et al. The earliest toothless hominin skull. *Nature*. 2005; 434:717–8.
10. Lebel S, Trinkaus E. Middle Pleistocene human remains from the Bau de l'Aubesier. *J Hum Evol*. 2002; 43(5):659–85. PMID: 12457854
11. Gracia A, Arsuaga JL, Martínez I, Lorenzo C, Carretero JM, Bermúdez de Castro JM, et al. Craniosynostosis in a Middle Pleistocene human: Cranium 14 from the Sima de los Huesos, Atapuerca, Spain. *Proc Natl Acad Sci USA*. 2009; 106(16):6573–8. <https://doi.org/10.1073/pnas.0900965106> PMID: 19332773
12. Pérez PJ, Gracia A, Martínez I, Arsuaga JL. Paleopathological evidence of the cranial remains from the Sima de los Huesos Middle Pleistocene site (Sierra de Atapuerca, Spain). Description and preliminary inferences. *J Hum Evol*. 1997; 33(3):409–21.
13. Hauser G, DeStefano CF. Epigenetic Variants of the Human Skull. Stuttgart: Schweizerbart'sche; 1989.
14. Leonetti JP, Marzo SJ. Diseases of the external auditory canal. In: Pensak ML, Choo DI, editors. *Clinical Otology*, 4th ed. New York: Thieme; 2015. p. 181–91.
15. Graham MD. Osteomas and exostoses of the external auditory canal. A clinical, histopathologic and scanning electron microscopic study. *Ann Otol Rhinol Laryngol*. 1979; 88: 566–72. <https://doi.org/10.1177/000348947908800422> PMID: 475257
16. Villotte S, Knüsel CJ. External auditory exostoses and prehistoric aquatic resource procurement. *J Archaeol Sci Rep*. 2016; 6(4):633–6.

17. Kennedy GE. The relationship between auditory exostoses and cold water: a latitudinal analysis. *Am J Phys Anthropol.* 1986; 71(4):401–15. <https://doi.org/10.1002/ajpa.1330710403> PMID: 3812656
18. Deleyiannis FWB, Cockcroft BD, Pinczower EF. Exostoses of the external auditory canal in Oregon surfers. *Am J Otolaryngol.* 1996; 17(5):303–7. PMID: 8870934
19. Cooper A, Tong R, Neil R, Owens D, Tomkinson A. External auditory canal exostoses in white water kayakers. *Br J Sports Med.* 2010; 44:144–7. <https://doi.org/10.1136/bjsm.2008.048157> PMID: 18603582
20. Harrison DFN. The relationship of osteomata of the external auditory meatus to swimming. *Ann Roy Coll Surg Engl.* 1962; 31(9):187–201.
21. Filipo R, Fabiani M, Barbara M. External ear canal exostosis: a physiopathological lesion in aquatic sports. *J Sports Med.* 1982; 22:329–36.
22. Karegeannes JC. Incidence of bony outgrowths of the external ear canal in U.S. Navy divers. *Under-sea Hyperbaric Med.* 1995; 22(3):301–6.
23. Kroon DF, Lawson ML, Derkay CS, Hoffmann K, McCook J. Surfer's ear: External auditory exostoses are more prevalent in cold water surfers. *Otolaryngol Head Neck Surg.* 2002; 126(5):499–504. <https://doi.org/10.1067/mhn.2002.124474> PMID: 12075223
24. Altuna X, Gómez J, Luqui I, Vea JC, Algaba J. Prevalence of exostoses surfers of the Basque coast. *Acta Otorrinolaringol Esp.* 2004; 55:364–68. PMID: 15552211
25. Crowe F, Sperduti A, O'Connell TC, Craig OE, Kirsanow K, Germoni P, et al. Water-related occupations and diet in two Roman coastal communities (Italy, first to third century AD): correlation between stable carbon and nitrogen isotope values and auricular exostosis prevalence. *Am J Phys Anthropol.* 2010; 142(3):355–66. <https://doi.org/10.1002/ajpa.21229> PMID: 20014179
26. Villotte S, Stefanović S, Knüsel CJ. External auditory exostoses and aquatic activities during the Mesolithic and the Neolithic in Europe: results from a large prehistoric sample. *Anthropol (Brno).* 2014; 52(1):73–89.
27. Standen VG, Arriaza B, Santoro CM. External auditory exostosis in prehistoric Chilean populations: a test of the cold water hypothesis. *Am J Phys Anthropol.* 1997; 103(1):119–29. [https://doi.org/10.1002/\(SICI\)1096-8644\(199705\)103:1<119::AID-AJPA8>3.0.CO;2-R](https://doi.org/10.1002/(SICI)1096-8644(199705)103:1<119::AID-AJPA8>3.0.CO;2-R) PMID: 9185955
28. Velasco-Vázquez J, Betancor-Rodríguez A, Arnay-de-la-Rosa M, González-Reimers E. Auricular exostoses in the prehistoric population of Gran Canaria. *Am J Phys Anthropol.* 2000; 112(1):49–55. [https://doi.org/10.1002/\(SICI\)1096-8644\(200005\)112:1<49::AID-AJPA6>3.0.CO;2-U](https://doi.org/10.1002/(SICI)1096-8644(200005)112:1<49::AID-AJPA6>3.0.CO;2-U) PMID: 10766943
29. Kuzminsky SC, Erlandson JM, Xifara T. External auditory exostoses and its relationship to prehistoric abalone harvesting on Santa Rosa Island, California. *Int J Osteoarchaeol.* 2016; 26:1014–23.
30. Arnay-de-la-Rosa M, González-Reimers E, Velasco-Vázquez J, Santolària-Fernández F. Auricular exostoses among the prehistoric population of different islands of the Canary archipelago. *Ann Otol Rhinol Laryngol.* 2001; 110(11):1080–3. <https://doi.org/10.1177/000348940111001117> PMID: 11713923
31. Okamura MMM, Boyadjian CHC, Eggers S. Auditory exostoses as an aquatic activity marker: A comparison of coastal and inland skeletal remains from tropical and subtropical regions of Brazil. *Am J Phys Anthropol.* 2007; 132: 558–67. <https://doi.org/10.1002/ajpa.20544> PMID: 17243122
32. Mazza B. Auditory exostoses in Pre-Hispanic populations of the Lower Paraná wetlands, Argentina. *Int J Osteoarchaeol.* 2016; 26:420–430.
33. Katayama K. Auditory exostoses among ancient human populations in the Circum-Pacific area: Regional variation in the occurrence and its implications. *Anthropol Sci.* 1998; 106(4): 285–96.
34. Ponce P, Ghidini G, González-José R. External auditory exostosis “at the end of the world”: the southernmost evidence according to the latitudinal hypothesis. *Brit Archaeol Rep.* 2008; S1743: 101–7.
35. Weidenreich F. The skull of *Sinanthropus pekinensis*. *Palaeontol Sinica.* 1943; 10D:1–485.
36. Boule M. L'homme fossile de La Chapelle-aux-Saints. *Ann Paléontol.* 1911–13; 6:111–72; 7:21–56, 85–192; 8:1–70.
37. Stewart TD. The restored Shanidar I skull. *Sumer.* 1958; 14(1):90–95.
38. Condemi S. Les Néandertaliens de La Chaise. Paris: Comité des Travaux Historiques et Scientifiques; 2001.
39. Li ZY, Wu XJ, Zhou LP, Liu W, Gao X, et al. Late Pleistocene archaic human crania from Xuchang, China. *Science.* 2017; 355:969–72. <https://doi.org/10.1126/science.aal2482> PMID: 28254945
40. Suzuki H. Skulls of the Minatogawa man. *Bull Univ Mus Univ Tokyo.* 1982; 19:7–49.
41. Verna C. Les Restes Humains Moustériens de la Station Amont de La Quina (Charente, France) [dissertation]. Bordeaux: Université de Bordeaux 1; 2006.

42. Villotte S, Samsel M, Sparacello V. The paleobiology of two adult skeletons from Baouso da Torre (Bausu da Ture) (Liguria, Italy): Implications for Gravettian lifestyle. *C R Palevol*. 2017; 16:462–73.
43. Trinkaus E, Buzhilova AP, Mednikova MB, Dobrovolskaya MV. *The People of Sungir: New York: Oxford University Press; 2014.*
44. Stewart TD. The Neanderthal skeletal remains from Shanidar Cave, Iraq: A summary of findings to date. *Proc Am Phil Soc*. 1977; 121(2):121–165.
45. Trinkaus E, Thompson DD. Femoral diaphyseal histomorphometric age determinations for the Shanidar 3, 4, 5 and 6 Neandertals and Neandertal longevity. *Am J Phys Anthropol*. 1987; 72:123–29. <https://doi.org/10.1002/ajpa.1330720115> PMID: 3103459
46. Jackson G. The etiology of exostoses of the external auditory meatus. *Br Med J*. 1909; 2 (2546):1137–8.
47. DiBartolomeo JR. Exostoses of the external auditory canal. *Ann Otol Rhinol Laryngol*. 1979; 88 (6S):1–20.
48. Roland PS, Marple BF. Disorders of the external auditory canal. *J Am Acad Audiol*. 1997; 8(6):367–378. PMID: 9433682
49. Rabach LA, Kveton JF. Clinical evaluation of hearing loss. In: Pensak ML, Choo DI, editors. *Clinical Otology*, 4th ed. New York: Thieme; 2015. p. 139–47.
50. White RD, Ananthakrishnan G, McKean SA, Brunton JN, Hussain SSM, Sudarshan TA. Masses and disease entities of the external auditory canal: radiological and clinical correlation. *Clin Radiol*. 2011; 67(2):172–81. <https://doi.org/10.1016/j.crad.2011.08.019> PMID: 22018812
51. Whitaker SR, Cordier A, Kosjakov S, Charbonneau R. Treatment of external auditory canal exostoses. *Laryngoscope*. 1998; 108(2):195–9. PMID: 9473067
52. Guest JF, Greener MJ, Robinson AC, Smith AF. Impacted cerumen: composition, production, epidemiology and management. *Quart J Med*. 2004; 97(8):477–88.
53. Kesser BW, Choo DI. Aural atresia and unilateral hearing loss. In: Pensak ML, Choo DI, editors. *Clinical Otology*, 4th ed. New York: Thieme; 2015. p. 192–201.
54. Chia EM, Wang JJ, Rochtchina E, Cumming RR, Newall P, Mitchell P. Hearing impairment and health-related quality of life: The Blue Mountain hearing study. *Ear Hearing*. 2007; 28(2):187–195. <https://doi.org/10.1097/AUD.0b013e31803126b6> PMID: 17496670
55. Dalton DS, Cruickshanks KJ, Klein BEK, Klein R, Wiley TL, Nondahl DM. The impact of hearing loss on quality of life in older adults. *Gerontologist*. 2003; 43(5):661–668. PMID: 14570962
56. Ciorba A, Bianchini C, Pelucchi S, Pastore A. The impact of hearing loss on the quality of life of elderly adults. *Clin Intervent Aging*. 2012; 2012(7):159–163.
57. Boë LJ, Heim JL, Honda K, Maeda S, Badin P, Abry C. The vocal tract of newborn humans and Neandertals: Acoustic capabilities and consequences for the debate on the origin of language. *J Phonetics*. 2007; 35(4):564–581.
58. Krause J, Lalueza-Fox C, Orlando L, Enard W, Green RE, Burbano HA, et al. The derived FOXP2 variant of modern humans was shared with Neandertals. *Curr Biol*. 2007; 17(21):1908–12. <https://doi.org/10.1016/j.cub.2007.10.008> PMID: 17949978
59. Martínez I, Rosa M, Quam R, Jarabo P, Lorenzo C, Bonmatí A, et al. Communicative capacities in Middle Pleistocene humans from the Sierra de Atapuerca in Spain. *Quatern Intl*. 2013; 295(1):94–101.
60. Apicella CL. Upper-body strength predicts hunting reputation and reproductive success in Hadza hunter-gatherers. *Evol Hum Beh*. 2014; 35(6):508–18.
61. Putt SS, Wijekumar S, Franciscus RG, Spencer JP. The functional brain networks that underlie Early Stone Age tool manufacture. *Nature Hum Beh*. 2017; 1:0102. <https://doi.org/10.1038/s41562-017-0102>
62. Rosell J, Baquedano E, Blasco R, Camarós E, editors. New insights on hominid-carnivore interactions during the Pleistocene. *J Taphonomy*. 2012; 10(3/4):125–576.
63. Mashkour M, Monchot H, Trinkaus E, Reyss JL, Biglari F, Bailon S, et al. Carnivores and their prey in the Wezmeh Cave, (Kermanshah, Iran): A Late Pleistocene refuge in the Zagros. *Intl J Osteoarchaeol*. 2009; 19(6):678–94
64. Evins MA. The fauna from Shanidar Cave: Mousterian wild goat exploitation in northeastern Iraq. *Paléorient*. 1982; 8(1):37–58.
65. Crubézy E, Trinkaus E. Shanidar 1: A case of hyperostotic disease (DISH) in the Middle Paleolithic. *Am J Phys Anthropol*. 1992; 89(4):411–20. <https://doi.org/10.1002/ajpa.1330890402> PMID: 1463085

66. Arsuaga JL, Martínez I, Arnold LJ, Aranburu A, Gracia-Téllez A, Sharp WD, et al. Neandertal roots: Cranial and chronological evidence from Sima de los Huesos. *Science*. 2014; 344(6190):1358–63. <https://doi.org/10.1126/science.1253958> PMID: 24948730
67. De La Cruz A, Chandrasekhar SS. Congenital malformation of the temporal bone. In: Brackmann DE, Shelton C, Arriaga M, editors. *Otologic Surgery*. Philadelphia: Saunders; 2001. p. 54–67.
68. Abdel-Aziz M. Congenital aural atresia. *J Craniofac Surg*. 2013; 24(4):e418–e422.
69. Hublin JJ. The prehistory of compassion. *Proc Natl Acad Sci USA*. 2009; 106(16):6429–30. <https://doi.org/10.1073/pnas.0902614106> PMID: 19380715
70. DeGusta D. Comparative skeletal pathology and the case for conspecific care in middle Pleistocene hominids. *J Archaeol Sci*. 2002; 29(12):1435–8.
71. Cuozzo FP, Sauter ML. Tooth loss, survival, and resource use in wild ringtailed lemurs (*Lemur catta*): implications for inferring conspecific care in fossil hominids. *J Hum Evol*. 2004; 46(5):623–31. <https://doi.org/10.1016/j.jhevol.2004.02.004> PMID: 15120269
72. Turner SE, Fedigan LM, Matthews HD, Nakamichi M. Social consequences of disability in a nonhuman primate. *J Hum Evol*. 68(1):47–57.
73. Matsumoto T, Itoh N, Inoue S, Nakamura M. An observation of a severely disabled infant chimpanzee in the wild and her interactions with her mother. *Primates*. 2016; 57(1):3–7. <https://doi.org/10.1007/s10329-015-0499-6> PMID: 26553203
74. Reynolds V. Some behavioral comparisons between the chimpanzee and the mountain gorilla in the wild. *Am Anthropol*. 1965; 67:691–706.
75. Byrne RW, Stokes EJ. Effects of manual disability on feeding skills in gorillas and chimpanzees. *Intl J Primatol*. 2002; 23(3):539–54.
76. Cibot M, Krief S, Philippon J, Couchoud P, Seguya A, Pouydebat E. Feeding consequences of hand and foot disability in wild adult chimpanzees (*Pan troglodytes schweinfurthii*). *Intl J Primatol*. 2016; 37:479–94.
77. Lovell NC. *Patterns of Injury and Illness in Great Apes*. Washington, DC: Smithsonian Institution Press; 1990.
78. Patte E. *L'Enfant Néanderthalien du Pech de l'Azé*. Paris: Masson; 1957.
79. Trinkaus E, Churchill SE, Ruff CB. Postcranial robusticity in *Homo*, II: Humeral bilateral asymmetry and bone plasticity. *Am J Phys Anthropol*. 1994; 93:1–34. <https://doi.org/10.1002/ajpa.1330930102> PMID: 8141238
80. Trinkaus E. *The Krapina Human Postcranial Remains*. Zagreb: FF Press; 2016.
81. Trinkaus E. Pathology and the posture of the La Chapelle-aux-Saints Neandertal. *Am J Phys Anthropol*. 1985; 67(1):19–41. <https://doi.org/10.1002/ajpa.1330670105> PMID: 3904471
82. Sergi S. *Il Cranio Neanderthaliano del Monte Circeo (Circeo I)*. Rome: Accademia Nazionale dei Lincei; 1974.
83. Rendu W, Beauval C, Crevecoeur I, Bayle P, Balzeau A, Bismuth T, et al. Evidence supporting an intentional Neandertal burial at La Chapelle-aux-Saints. *Proc Natl Acad Sci USA*. 2014; 111(1):81–6. <https://doi.org/10.1073/pnas.1316780110> PMID: 24344286
84. Binford LR. Mortuary practices: Their study and their potential. *Mem Soc Am Archaeol*. 1971; 25(1):6–29.
85. Tainter JA. Mortuary practices and the study of prehistoric social systems. *Adv Archaeol Meth Theory*. 1978; 1:105–41.
86. Trinkaus E. Neandertal gene speaks out. *Curr Biol*. 2007; 17(21):R917–R919. <https://doi.org/10.1016/j.cub.2007.09.055> PMID: 17983567
87. Zilhão J, Angelucci DE, Badal-García E, d'Errico F, Daniel F, Dayet L, et al. Symbolic use of marine shells and mineral pigments by Iberian Neandertals. *Proc Natl Acad Sci USA*. 2010; 107(3):1023–8. <https://doi.org/10.1073/pnas.0914088107> PMID: 20080653
88. Peresani M, Fiore I, Gala M, Romandini M, Tagliacozzo A. Late Neandertals and the intentional removal of feathers as evidenced from bird bone taphonomy at Fumane Cave 44 ky B.P., Italy. *Proc. Natl Acad Sci USA*. 2011; 108(10):3888–93. <https://doi.org/10.1073/pnas.1016212108> PMID: 21368129
89. d'Errico F, Soressi M. Systematic use of manganese pigment by the Pech-de-l'Azé Neandertals: implications for the origin of behavioral modernity. *J Hum Evol*. 2002; 42:A13.
90. Cârciușmaru M, Țuțuianu-Cârciușmaru M. L'ocre et les récipients pour ocre de la grotte Cioarei. *Ann Univ Valahia Targoviste—Sect Archéol Hist*. 2009; 11:7–19.

91. Meignen L. Répartition spatiale des vestiges au sol de l'abri des Canalettes. In: Meignen L, editor. *L'Abri des Canalettes*. Paris: C.N.R.S. 1993; p. 161–97.
92. GEPP (Grupo para Estudo do Paleolítico Português). A estação paleolítica de Vilas Ruivas (Ródão)—campanha de 1979. *Arqueol Portug*. 1983; Série IV, 1:15–38.
93. Bar-Yosef O, Vandermeersch B, Arensburg B, Belfer-Cohen A, Goldberg P, Laville H, et al. 1992. The excavations in Kebara Cave, Mt. Carmel. *Curr Anthropol*. 1992; 33:497–550.
94. Jaubert J, Verheyden S, Genty D, Soulier M, Cheng H, Blamart D, et al. Early Neanderthal constructions deep in Bruniquel Cave in southwestern France. *Nature*. 2016; 534:111–4. <https://doi.org/10.1038/nature18291> PMID: 27251286
95. Estalrich A, Rosas A. Division of labor by sex and age in Neandertals: an approach through the study of activity-related dental wear. *J Hum Evol*. 2015; 80(1):51–63.
96. Sparacello VS, Villotte S, Shackelford LL, Trinkaus E. Patterns of humeral asymmetry among Late Pleistocene humans. *C R Palevol*. 2016; <https://doi.org/10.1016/j.crpv.2016.09.001>
97. Trinkaus E. European early modern humans and the fate of the Neandertals. *Proc Natl Acad Sci USA*. 2007; 104(18):7367–72. <https://doi.org/10.1073/pnas.0702214104> PMID: 17452632
98. Fu QM, Posth C, Hajdinjak M, Petr M, Mallick S, Fernandes D, et al. The genetic history of ice age Europe. *Nature*. 2016; 534:200–5. <https://doi.org/10.1038/nature17993> PMID: 27135931
99. Villa P, Roebroeks W. Neandertal demise: An archaeological analysis of the modern human superiority complex. *PloS ONE*. 2014; 9(4):e96424. <https://doi.org/10.1371/journal.pone.0096424> PMID: 24789039
100. Trinkaus E. The paleobiology of modern human emergence. In: Smith FH, Ahern JCM, editors. *Origins of Modern Humans: Biology Reconsidered*. Hoboken: Wiley; 2013; p. 393–434.
101. Roebroeks W, Soressi M. Neandertals revisited. *Proc Natl Acad Sci USA*. 2016; 113(23):6372–9. <https://doi.org/10.1073/pnas.1521269113> PMID: 27274044