
January 1992

A Synopsis of Disease Conditions Found in Wild Turkeys (meleagris Gallopavo L) from Florida, 1969-1990

Donald J. Forrester

Follow this and additional works at: <https://digitalcommons.usf.edu/ffn>

Recommended Citation

Forrester, Donald J. (1992) "A Synopsis of Disease Conditions Found in Wild Turkeys (meleagris Gallopavo L) from Florida, 1969-1990," *Florida Field Naturalist*. Vol. 20 : Iss. 2 , Article 1.
Available at: <https://digitalcommons.usf.edu/ffn/vol20/iss2/1>

This Contents is brought to you for free and open access by Digital Commons @ University of South Florida. It has been accepted for inclusion in Florida Field Naturalist by an authorized editor of Digital Commons @ University of South Florida. For more information, please contact digitalcommons@usf.edu.

Florida Field Naturalist

PUBLISHED BY THE FLORIDA ORNITHOLOGICAL SOCIETY

VOL. 20, No. 2

MAY 1992

PAGES 29-56

Fla. Field Nat. 20(2): 29-35, 1992.

A SYNOPSIS OF DISEASE CONDITIONS FOUND IN WILD TURKEYS (*MELEAGRIS GALLOPAVO* L.) FROM FLORIDA, 1969-1990

DONALD J. FORRESTER

*Department of Infectious Diseases, College of Veterinary Medicine,
University of Florida, Gainesville, Florida 32610*

Abstract.—From 1 July 1969 through 31 December 1990 diagnostic evaluations were conducted on 76 Wild Turkeys (*Meleagris gallopavo* L.) from various locations in Florida. These included six turkeys categorized as road-kills and four as cases of predation or hunter-inflicted trauma, and 66 which were sick or died due to such factors as anomalies, neoplasia, and nutritional, viral, bacterial, mycotic, and parasitic diseases. The most common and widespread disease was avian pox which was diagnosed in 42 turkeys from 19 counties throughout the state. Most were cutaneous infections, but five involved the oral cavity as well, and one case was only in the oral cavity. Less frequent diagnoses included a lymphoproliferative disease, mycotic dermatitis, infectious enterohepatitis, malaria, protozoal myositis, salmonellosis, bumblefoot, bacterial pneumonia, abscesses, a deformed mandible, and emaciation.

In the mid-1960s sudden and marked declines in the population of Wild Turkeys in Florida were noted by management biologists (Williams and Austin 1988). The statewide harvest of turkeys by hunters in 1968 was the lowest on record (Hon et al. 1975). An infectious disease was suspected and in July of 1969 a cooperative study between the College of Veterinary Medicine at the University of Florida and the Florida Game and Fresh Water Fish Commission was initiated. Its purpose was to determine the prevalence, distribution, and impact of parasites and diseases of Wild Turkeys in Florida in order to gain a basic understanding of these factors so that if another die-off occurred, a correct diagnosis could be made rapidly and management and control actions taken in a timely fashion. As a result of that study a number of reports were published on disease agents including viruses (Busch and Williams 1970, Colwell et al. 1973, Grant et al. 1975, Akey et al. 1981), bacteria (White et al. 1981), protozoans (Forrester et al. 1974, Telford and Forrester 1975, Greiner and Forrester 1980, Atkinson and Forrester 1987), and helminths (Hon et al. 1975 and 1978). The present report is concerned with results of diagnostic examinations of Wild Turkeys in Florida over

a 21-year period. These data should be considered from the viewpoint expressed by Davidson et al. (1985) who stressed that these types of accessions do not allow a completely accurate assessment of the importance of natural mortality factors. This is largely because turkeys were not sampled in a random fashion from the population in Florida. It is also probable that birds with obvious lesions such as those produced by poxvirus may be submitted more frequently and this would tend to bias the sample. However, this information is still of value in identifying probable morbidity and mortality factors, when interpreted with caution.

MATERIALS AND METHODS

Records on necropsy and laboratory examinations of 76 Wild Turkeys which had been submitted for evaluation were reviewed for the period 1 July 1969 through 31 December 1990. These turkeys originated from throughout the state of Florida; most had been submitted by personnel of the Florida Game and Fresh Water Fish Commission, whereas a few came from private individuals. Some specimens were compromised by postmortem changes or improper preservation of samples or carcasses and this precluded the use of certain laboratory procedures. However, appropriate tests were conducted and when possible a complete necropsy was performed. When necessary, samples for histopathology, toxicology, microbiology, parasitology, hematology, and serology were collected and processed following standard laboratory procedures. Cases were grouped according to the categories of morbidity and mortality presented by Hayes and Prestwood (1969).

RESULTS AND DISCUSSION

On the 76 turkeys examined (Table 1), ten had been injured or killed due to trauma, probably by being struck by vehicles on highways ($n=6$) or because of predator- or hunter-inflicted injuries ($n=4$). The other 66 turkeys were sick or died due to other factors including anomalies, neoplasia, and nutritional, viral, bacterial, mycotic, and parasitic diseases.

The most common and widespread disease was avian pox (Table 1), which was found in 42 of the turkeys examined. These infected birds originated from 19 counties distributed throughout the state (Fig. 1). In addition to the data presented here, there are records of avian pox in Wild Turkeys from four other counties in Florida: Bay (W. R. Davidson, pers. comm.), Gadsden and Liberty (N. F. Eichholz, pers. comm.), and Volusia (Powell 1965). Pox is caused by a virus (Poxviridae) and is characterized by discrete (and sometimes coalescing), proliferative lesions on the skin, particularly on the unfeathered regions of the head and legs, and on the mucus membranes of the oral cavity and upper respiratory tract (Karstad 1971). Most of the infections seen in Wild Turkeys in Florida involved the skin of the head; five involved the oral cavity as well, and one case was only in the oral cavity. The severity of pox infections varies. Most cases are inconsequential, but when lesions involve the eyelids, corners of the mouth, or oral membranes, they can lead to

Table 1. Diagnostic findings in 76 Wild Turkeys from Florida, 1969-1990.

Category	Diagnosis	No. of cases*
Anomalies	Deformed upper mandible	1
Trauma	Road-kills	6
	Predation	4
Neoplasia	Lymphoproliferative disease	12
Nutritional diseases	Emaciation	1
Viral diseases	Avian pox	42
Mycotic diseases	Dermatitis	5
Bacterial diseases	Salmonellosis	2
	Abscesses	2
	Bumblefoot	1
	Pneumonia	1
Parasitic diseases	Infectious enterohepatitis	3
	Malaria	2
	Protozoal myositis	1

*Total does not add up to 76 because three turkeys had pox and lymphoproliferative disease (LPD), one had pox and a liver abscess, one had pox and infectious enterohepatitis, one had LPD and dermatitis, and one had myositis and dermatitis.

visual problems, respiratory distress, emaciation and weakness (Davidson and Nettles 1988). Turkeys with severe lesions of the eyelids in which vision is compromised can experience an increased risk of predation (Forrester 1991). In addition to mechanical transfer of the virus by direct or indirect contact, mosquitoes are known to be mechanical vectors (DaMassa 1966, Karstad 1971) and are probably the most significant means of transmission in Florida. The lesions seen commonly on the head, legs, and other featherless areas of the skin of Wild Turkeys have developed at the sites of mosquito bites. The occurrence of these lesions on the head has led many biologists, naturalists, and hunters to refer to this disease as "sorehead." The vectors in Florida include several species of culicine mosquitoes which usually occur in highest numbers during late summer and early fall and this is when most pox infections occur (Akey et al. 1981, Forrester 1991). Once a turkey is infected with pox and recovers, it is usually immune for life (Tripathy 1991). However, if pox infections occur in the spring or early summer (due to abnormally high amounts of rainfall and its subsequent stimulation of breeding activity in mosquito populations) the result can have a devastating effect on young

poults who lack immunity and are particularly susceptible to the disease (Forrester 1991). Information on pox infection reported here and in other studies supports the conclusions of Davidson et al. (1985) that avian pox is an important infectious disease of Wild Turkeys in the Southeast. Certainly this is true for Florida. Because of its high prevalence and probable significance as a mortality factor, this disease warrants further study in Florida in order to understand its ecology and effects on populations of Wild Turkeys.

Five turkeys with mycotic dermatitis were diagnosed from Citrus, Gadsden, Glades, Osceola, and Taylor counties. The species of fungus involved was not determined for any of the cases; attempts to culture the organisms were unsuccessful. Several of these cases were severe, involving the exposed skin of the head and legs. These may have been sequelae to pox infections, although this could not be determined. Similar cases have been observed by personnel of the Southeastern Cooperative

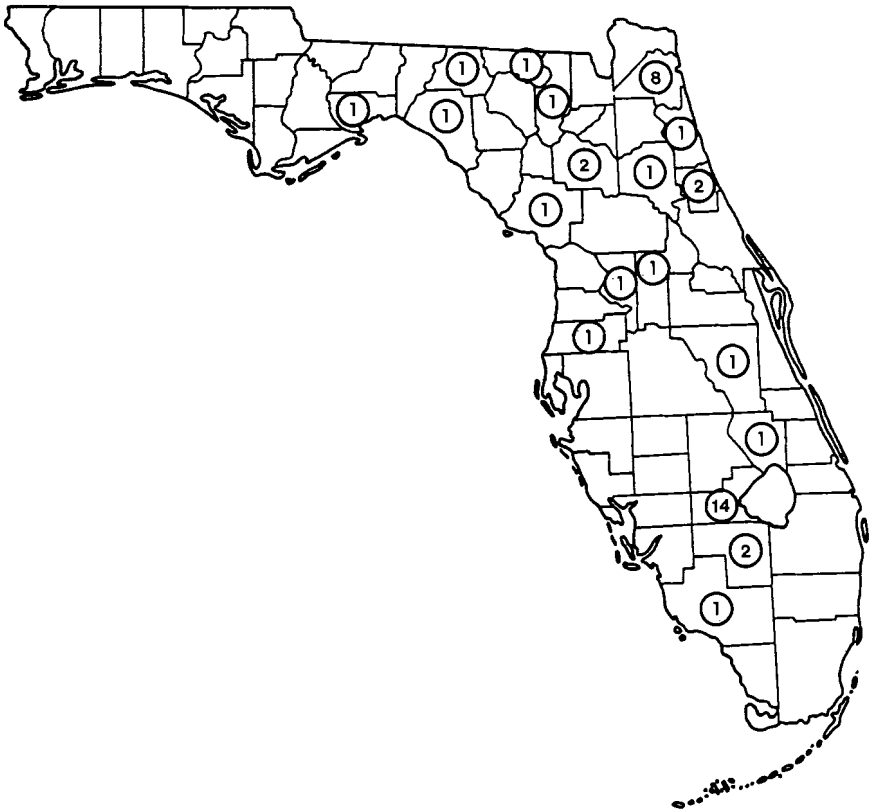


Figure 1. Map of Florida showing distribution by county of Wild Turkeys found with avian pox, 1969-1990. Numbers of infected turkeys are shown within the circles.

Wildlife Disease Study in Athens, Georgia, in which pox inclusions have been demonstrated, but only in a few instances (W. R. Davidson, pers. comm.).

A type of lymphoproliferative disease was diagnosed in turkeys from Alachua ($n=1$), Columbia ($n=1$), Duval ($n=1$), Glades ($n=6$), Levy ($n=2$), and Taylor ($n=1$) counties. Two of these cases have been discussed in more detail elsewhere by Busch and Williams (1970) who referred to the disease as a "Marek's disease-like condition." Subsequent work in Florida resulted in the isolation of a herpesvirus from a number of Wild Turkeys, but there is no evidence that this virus is related to the lymphoproliferative lesions (Colwell et al. 1973, Grant et al. 1975). This disease may actually be reticuloendotheliosis, a type of lymphoproliferative disease found sporadically in domestic turkeys in United States (Witter 1991) and reported recently from Wild Turkeys in North Carolina (Ley et al. 1989) and Georgia (Hayes et al. 1992). Reticuloendotheliosis is caused by a retrovirus, and isolation and identification of the virus are necessary for a definitive diagnosis; this has not been done in Florida. The significance of this neoplastic disease to populations of Wild Turkeys in Florida is not known.

Infectious enterohepatitis (also known as blackhead or histomoniasis) was found in three Wild Turkeys, one from Duval and two from Glades counties. This protozoan disease is probably not an important health factor in Wild Turkey populations in Florida, although it is said to be significant in other areas of the southeastern United States (Hurst 1980, Davidson et al. 1985). This may be related to the low prevalence in Florida of *Heterakis gallinarum*, the nematode which transmits *Histomonas meleagridis*, the etiologic agent of infectious enterohepatitis (Hon et al. 1975).

Two other protozoan diseases, malaria (caused by *Plasmodium hermani*) and protozoal myositis (caused by *Haemoproteus meleagridis*), were observed. Malaria occurred in two turkeys, one from Citrus County and one from Leon County; the turkey with myositis came from Orange County. Additional details of this myositis case are given by Atkinson and Forrester (1987). The effects of infections by these two arthropod-borne parasites may be more significant than these data indicate. Both are known to cause morbidity and mortality in young poults under experimental conditions (Forrester et al. 1980, Forrester 1991, Atkinson et al. 1988), and concurrent infections of pox and malaria are known to be especially harmful (Forrester 1991). Since pox, malaria, and haemoproteid infections are all prevalent and widespread in Florida (Forrester et al. 1974, Akey et al. 1981), the effects of these diseases may be significant, but poorly appreciated due to the difficulty of obtaining poults from the wild for diagnostic evaluations.

Eight of the 12 fundamental causes of morbidity and mortality of wildlife (Hayes and Prestwood 1969) were represented in the present study. Most of the cases (88%) fell into four of the categories, i.e., trauma, viral diseases, neoplasia, and parasitic diseases. These, especially the latter three, deserve more emphasis in future research efforts. The various conditions discussed in this paper can cause sickness and death, are relevant to the health of Wild Turkeys, and almost certainly play a role in the population dynamics of the species over the long term, even though that role is not well understood at this time.

ACKNOWLEDGMENTS

L. E. Williams, Jr. and D. H. Austin, formerly of the Florida Game and Fresh Water Fish Commission, were instrumental in obtaining most of the turkey specimens examined, and their friendship and assistance were very much appreciated. I thank N. F. Eichholz of the Florida Game and Fresh Water Fish Commission for providing unpublished information on pox infections in turkeys in Gadsden and Liberty counties. I also acknowledge with gratitude the assistance and advice of R. H. Busch, W. M. Colwell, J. M. Gaskin, E. C. Greiner, W. O. Iverson, K. D. Ley, C. F. Simpson, F. H. White, and M. D. Young, all colleagues at the University of Florida. In addition I also acknowledge the technicians, graduate students, and postdoctoral associates from my laboratory who worked on various phases of the turkey project over the years. These included B. L. Akey, R. M. Anderson, C. T. Atkinson, J. A. Conti, G. W. Foster, L. T. Hon, P. P. Humphrey, J. M. Kinsella, L. G. Rickard, M. G. Spalding, S. R. Telford, Jr., E. J. Wright, S. D. Wright, and others. I also thank W. R. Davidson of the Southeastern Cooperative Wildlife Disease Study for permission to cite the unpublished record of pox in a turkey from Bay County and for his comments on an early draft of this paper. This research was supported in part by grants and contracts from the Florida Game and Fresh Water Fish Commission's Federal Aid to Wildlife Restoration Program, Florida Pittman-Robertson Project W-41. This is Florida Agricultural Experiment Stations Journal Series No. R-01865.

LITERATURE CITED

- AKEY, B. L., J. K. NAYAR, AND D. J. FORRESTER. 1981. Avian pox in Florida Wild Turkeys: *Culex nigripalpus* and *Wyeomyia vanduzeei* as experimental vectors. *J. Wildl. Dis.* 17: 597-599.
- ATKINSON, C. T., AND D. J. FORRESTER. 1987. Myopathy associated with megaloschizonts of *Haemoproteus meleagridis* in a Wild Turkey from Florida. *J. Wildl. Dis.* 23: 495-498.
- ATKINSON, C. T., D. J. FORRESTER, AND E. C. GREINER. 1988. Pathogenicity of *Haemoproteus meleagridis* (Haemosporina: Haemoproteidae) in experimentally infected domestic turkeys. *J. Parasitol.* 74: 228-239.
- BUSCH, R. H., AND L. E. WILLIAMS, JR. 1970. A Marek's disease-like condition in Florida turkeys. *Avian Dis.* 4: 550-554.
- COLWELL, W. M., C. F. SIMPSON, L. E. WILLIAMS, JR., AND D. J. FORRESTER. 1973. Isolation of a herpesvirus from Wild Turkeys in Florida. *Avian Dis.* 17: 1-11.
- DAMASSA, A. J. 1966. The role of *Culex tarsalis* in the transmission of fowl-pox virus. *Avian Dis.* 10: 57-66.
- DAVIDSON, W. D., AND V. F. NETTLES. 1988. Field manual of wildlife diseases in southeastern United States. Athens, Georgia, Southeastern Cooperative Wildlife Disease Study, University of Georgia.

- DAVIDSON, W. D., V. F. NETTLES, C. E. COUVILLION, AND E. W. HOWERTH. 1985. Diseases diagnosed in Wild Turkeys (*Meleagris gallopavo*) of the southeastern United States. *J. Wildl. Dis.* 21: 386-390.
- FORRESTER, D. J. 1991. The ecology and epizootiology of avian pox and malaria in Wild Turkeys. *Bull. Soc. Vector Ecol.* 16: 127-148.
- FORRESTER, D. J., L. T. HON, L. E. WILLIAMS, JR., AND D. H. AUSTIN. 1974. Blood protozoa of Wild Turkeys in Florida. *J. Protozool.* 21: 494-497.
- FORRESTER, D. J., P. P. HUMPHREY, S. R. TELFORD, JR., AND L. E. WILLIAMS, JR. 1980. Effects of blood-induced infections of *Plasmodium hermani* on domestic and Wild Turkey poults. *J. Wildl. Dis.* 16: 237-244.
- GRANT, H. G., K. D. LEY, AND C. F. SIMPSON. 1975. Isolation and characterization of a herpesvirus from Wild Turkeys (*Meleagris gallopavo osceola*) in Florida. *J. Wildl. Dis.* 11: 562-565.
- GREINER, E. C., AND D. J. FORRESTER. 1980. *Haemoproteus meleagridis* Levine 1961: Redescription and developmental morphology of the gametocytes in turkeys. *J. Parasitol.* 66: 652-658.
- HAYES, F. A., AND A. K. PRESTWOOD. 1969. Some considerations for diseases and parasites of white-tailed deer in the southeastern United States. Pp. 32-36 in *Proceedings of White-tailed Deer in the Southern Forest Habitat Symposium*. Nacogdoches, Texas, U.S. Dept. Agric. For. Serv. So. For. Exp. Sta.
- HAYES, L. E., K. A. LANGHEINRICH, AND R. L. WITTER. 1992. Reticuloendotheliosis in a Wild Turkey (*Meleagris gallopavo*) from coastal Georgia. *J. Wildl. Dis.* 28: 154-158.
- HON, L. T., D. J. FORRESTER, AND L. E. WILLIAMS, JR. 1975. Helminths of Wild Turkeys in Florida. *Proc. Helminthol. Soc. Wash.* 42: 119-127.
- HON, L. T., D. J. FORRESTER, AND L. E. WILLIAMS, JR. 1978. Helminth acquisition by Wild Turkeys (*Meleagris gallopavo osceola*) in Florida. *Proc. Helminthol. Soc. Wash.* 45: 211-218.
- HURST, G. A. 1980. Histomoniasis in Wild Turkeys in Mississippi. *J. Wildl. Dis.* 16: 357-358.
- KARSTAD, L. A. 1971. Pox. Pp. 34-41 in *Infectious and parasitic diseases of wild birds* (J. W. Davis, R. C. Anderson, L. A. Karstad, and D. O. Trainer, eds.). Ames, Iowa, Iowa State University Press.
- LEY, D. H., M. D. FICKEN, D. T. COBB, AND R. L. WITTER. 1989. Histomoniasis and reticuloendotheliosis in a Wild Turkey (*Meleagris gallopavo*) in North Carolina. *J. Wildl. Dis.* 25: 262-265.
- POWELL, J. A. 1965. The Florida Wild Turkey. Tallahassee, Florida, Fla. Game & Fresh Water Fish Comm. Tech. Bull. No. 8.
- TELFORD, S. R., JR. AND D. J. FORRESTER. 1975. *Plasmodium (Huffia) hermani* sp. n. from Wild Turkeys (*Meleagris gallopavo*) in Florida. *J. Protozool.* 22: 324-328.
- TRIPATHY, D. N. 1991. Pox. Pp. 583-596 in *Diseases of poultry*. (B. W. Calnek, H. J. Barnes, C. W. Beard, W. M. Reid, and H. W. Yoder, Jr., eds.). Ames, Iowa, Iowa State University Press.
- WHITE, F. H., D. J. FORRESTER, AND L. E. WILLIAMS, JR. 1981. Isolations of *Salmonella* from Wild Turkeys in Florida. *J. Wildl. Dis.* 17: 327-330.
- WILLIAMS, L. E., AND D. H. AUSTIN. 1988. *Studies of the Wild Turkey in Florida*. Gainesville, Florida, University of Florida Press.
- WITTER, R. L. 1991. Reticuloendotheliosis. Pp. 439-456 in *Diseases of poultry*. (B. W. Calnek, H. J. Barnes, C. W. Beard, W. M. Reid, and H. W. Yoder, Jr., eds.). Ames, Iowa, Iowa State University Press.