

2019

Gram-Negative Rod Skin and Soft-tissue infections following Breast Tissue Expander Surgery in Breast Cancer Patients

Ju Hee Katzman

University of South Florida, juheekim@usf.edu

Sadaf Aslam

University of South Florida, saslam@usf.edu

Donna Mae M Pate

University of South Florida

Nicole Guidish

University of South Florida

Shelby Power

University of South Florida

See next page for additional authors

Follow this and additional works at: https://digitalcommons.usf.edu/intmed_facpub

Scholar Commons Citation

Katzman, Ju Hee; Aslam, Sadaf; Pate, Donna Mae M; Guidish, Nicole; Power, Shelby; Maravilla, Clarissa; Perkins, Janelle; and Greene, John, "Gram-Negative Rod Skin and Soft-tissue infections following Breast Tissue Expander Surgery in Breast Cancer Patients" (2019). *Internal Medicine Faculty Publications*. 133. https://digitalcommons.usf.edu/intmed_facpub/133

This Article is brought to you for free and open access by the Internal Medicine at Digital Commons @ University of South Florida. It has been accepted for inclusion in Internal Medicine Faculty Publications by an authorized administrator of Digital Commons @ University of South Florida. For more information, please contact scholarcommons@usf.edu.

Authors

Ju Hee Katzman, Sadaf Aslam, Donna Mae M Pate, Nicole Guidish, Shelby Power, Clarissa Maravilla, Janelle Perkins, and John Greene

use for SSTI is common. We determined the prevalence of SSTI and associated inappropriate antimicrobial use among inpatients in Sri Lanka.

Methods. A point-prevalence study of antimicrobial use was conducted using one-day cross-sectional surveys at five public hospitals in Southern Province, Sri Lanka from Jun-August 2017. Inpatients' medical records were reviewed for clinical data including antimicrobials prescribed. Inappropriate antimicrobial use was identified as (1) antimicrobial use discordant with guidelines by the Sri Lanka College of Microbiologists (SLCM), and (2) redundant combinations of antimicrobials.

Results. Of 1,709 surveyed patients, 935 (54.7%) received antimicrobials, of whom 779 (83.3%) had a specified or inferred indication for antimicrobial use. Among patients with an indication for antimicrobial use, SSTI was the second leading indication (181 patients, 23.2%) after lower respiratory tract infection (194, 24.9%). One-third (62, 34.2%) of patients with SSTI had a history of diabetes. Commonly used antimicrobials for SSTI included amoxicillin and clavulanic acid (40.3%), extended-spectrum penicillins (24.9%), and metronidazole (22.1%). Inappropriate antimicrobial use was observed in 53.0% of SSTI patients, with redundant antibiotic therapy in 35.9% and antimicrobials discordant with SLCM guidelines in 32.6%.

Conclusion. SSTI was a common reason for antimicrobial use among inpatients in Sri Lanka, with more than half of patients receiving potentially inappropriate antimicrobial therapy. We identified targets for future antimicrobial stewardship efforts.

Table 1:

Antimicrobials used for UTI	N (%)	Number of patients (%) receiving antimicrobials not recommended by the Guidelines	Number of patients (%) receiving redundant antimicrobials	Total patients receiving antimicrobials
Co-amoxiclav	73 (40.33)			
Extended-spectrum penicillins	45 (24.86)			
Metronidazole	40 (22.10)	59 (32.60)	65 (35.91)	181
Clindamycin	40 (22.10)			
Third-generation cephalosporins	25 (13.81)			

Table 2:

Hospital/ ward Characteristic	Inappropriate antimicrobial use		Appropriate antimicrobial use		P values
	No. (%)	No. (%)	No. (%)	No. (%)	
Tertiary level hospital	66 (68.75)	54 (63.53)			<.001
Secondary level hospital	21 (21.88)	27 (31.76)			
Primary level hospitals	9 (9.37)	4 (4.71)			
Overall	96 (100.0)	85 (100.0)			
Medical wards	28 (29.17)	23 (27.06)			<.001
Surgical wards	65 (67.71)	60 (70.59)			
Pediatric wards	1 (1.04)	1 (1.18)			
Intensive care units	2 (2.08)	1 (1.18)			
Overall	96 (100.0)	85 (100.0)			

Disclosures. All authors: No reported disclosures.

437. Gram-Negative Rod Skin and Soft-tissue infections following Breast Tissue Expander Surgery in Breast Cancer Patients

Ju Hee Katzman, MD¹; Sadaf Aslam, MD, MS¹; Donna Mae M. Pate, PharmD¹; Nicole Guidish, PharmD¹; Shelby Power, PharmD¹; Clarissa Maravilla, PharmD¹; Janelle Perkins, PharmD, BCOP¹ and John Greene, MD²; ¹University of South Florida, Tampa, Florida; ²Moffitt Cancer Center, Tampa, Florida

Session: 51. Soft Tissue and Skin Infections

Thursday, October 3, 2019: 12:15 PM

Background. Breast cancer patients who undergo tissue expander surgery (TES) are at an increased risk of developing gram-negative rod (GNR) skin and soft-tissue infection (SSIs) and its complications including prolonged antibiotic therapy, antibiotics side effects, and implant removal. Current perioperative antimicrobials focus mostly on gram-positive organisms, but the presence of a foreign body increases the risk of GNR SSI. We describe here the most common GNR bacteria and their susceptibility patterns that cause SSI after TES among breast cancer patients.

Methods. We conducted a retrospective cohort study at Moffitt Cancer Center, Tampa, FL from January 2016, to January 2018, on all breast cancer patients who developed GNR SSIs following TES. We reviewed records after approval from the Institutional Review Board. The data collected included patient's age, pathogens from wound culture, antibiotic susceptibilities, the perioperative and definitive antibiotics used.

Results. A total of 38 cases of GNR SSI with a mean age of 56 ± 11 years were identified. The 3 most common pathogens were *Pseudomonas aeruginosa* (45%), *Serratia marcescens* (16%), and *Klebsiella pneumoniae* (8%) (Figure 1). The susceptibility pattern was available for 33 cases. *Pseudomonas* and *Klebsiella* isolates were susceptible to all tested antibiotics (Table 1). The *Stenotrophomonas* isolates showed resistance to ceftazidime. *Enterobacter cloacae*, *Enterobacter aerogenes*, *Morganella morganii*, and *Acinetobacter baumannii* complex, showed resistance to cefazolin. Twenty-five cases (74%) received perioperative antibiotics for gram-positive organisms; mostly cefazolin, and vancomycin. The common antibiotics used for definitive treatment were ciprofloxacin, cefepime, ceftazidime, piperacillin-tazobactam, and meropenem.

Conclusion. In centers with a high percentage of GNR SSI following TES should consider using perioperative antibiotics that include coverage against *Pseudomonas aeruginosa*, the most common isolate (45%). The use only of cefazolin or other

antibiotics against gram-positive organism may be inadequate. However, GNR infection may occur from 48 hours to 2 weeks postoperatively and may be from the acquisition of the GNR at home in which perioperative antibiotics may have minimal effect.

Figure 1. Gram-Negative Rod Pathogens Isolated from Wound Cultures Among Breast Cancer Patients Who Developed Skin and Soft Tissue Infection following Breast Reconstructive Surgery, Moffitt Cancer Center, Tampa, 2016-2018. n=38 (%)

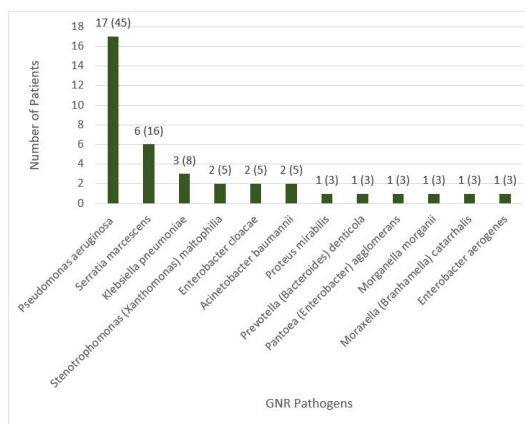


Table 1. In Vitro Susceptibility Profile of Gram-Negative Rod Pathogens Isolated from Wound Cultures Among Breast Cancer Patients Who Developed Skin and Soft Tissue Infection following Breast Reconstructive Surgery, Moffitt Cancer Center, Tampa, 2016-2018. n=33

Antibiotic	Susceptible, n (%)	Intermediate, n (%)	Resistant, n (%)
Ampicillin	1 (14%)	0	6 (86%)
Cefazolin	5 (31%)	0	11 (69%)
Cefoxitin	5 (31%)	1 (6%)	10 (63%)
Ceftazidime	1 (50%)	0	1 (50%)
Ampicillin/Sulbactam	6 (86%)	1 (14%)	0
Ceftriaxone	16 (94%)	1 (6%)	0
Cefepime	30 (100%)	0	0
Ciprofloxacin	31 (100%)	0	0
Levofloxacin	2 (100%)	0	0
Trimeth/Sulfa	17 (100%)	0	0
Piperacillin/Tazobactam	24 (100%)	0	0
Meropenem	1 (100%)	0	0
Tobramycin	31 (100%)	0	0
Gentamicin	31 (100%)	0	0
Amikacin	1 (100%)	0	0
Minocycline	2 (100%)	0	0

Disclosures. All authors: No reported disclosures.

438. Dalbavancin Clinical Experience at an NCI Designated Cancer Center

Patrick McDaniel, PharmD¹; Devlin Smith, PharmD, MS² and Frank Tverdek, PharmD³; ¹The University of Texas MD Anderson Cancer Center, Houston, Texas; ²University of Kentucky HealthCare, Lexington, Kentucky

Session: 51. Soft Tissue and Skin Infections

Thursday, October 3, 2019: 12:15 PM

Background. Dalbavancin (DAL) is a long-acting lipoglycopeptide, which allows for up to 2 weeks of therapy from a single dose. Outside of its FDA-approved indication for the treatment of acute bacterial skin and skin structure infections (ABSSSI), there is a growing interest in the utilization of DAL for other indications, including catheter-related bloodstream infection (CRBSI). The long-acting formulation potentially facilitates patient discharge or admission deferral without the need for daily outpatient parenteral antimicrobial therapy (OPAT). However, there is limited experience reporting DAL utilization in an oncology population. The objective of this study was to report our experience with DAL in an oncology patient population at a National Cancer Institute (NCI) Designated Cancer Center.

Methods. We conducted a retrospective review of all patients receiving DAL therapy in June 2016–June 2017. The primary outcome was a clinical success at 30 days (complete/partial resolution of symptoms without readmission for a same/similar infection), with secondary outcomes including readmission rate, acute kidney injury (AKI) incidence (Acute Kidney Injury Network [AKIN] criteria) and additional antimicrobial use within 30 days.

Results. We identified 76 unique subjects, with 77 unique infectious episodes, receiving 78 DAL doses. The majority of the subjects were male (57%), the median age was 61 years old, 55% had a solid tumor type and most were treated for ABSSSI (86%). Doses were administered inpatient 76% of the time and most patients received 1500 mg (90%). The most common pathogen isolated was *Staphylococcus aureus* (19%). Patients frequently received additional methicillin-resistant *Staphylococcus aureus* active oral antibiotics (39%). Clinical success was reported in 78% of infections. Potential DAL-related AKI was identified in 4 subjects (5%).

Conclusion. We reported on the use of DAL in a variety of oncology patients at a major cancer center. Clinical success was often achieved in ABSSSI with a single DAL